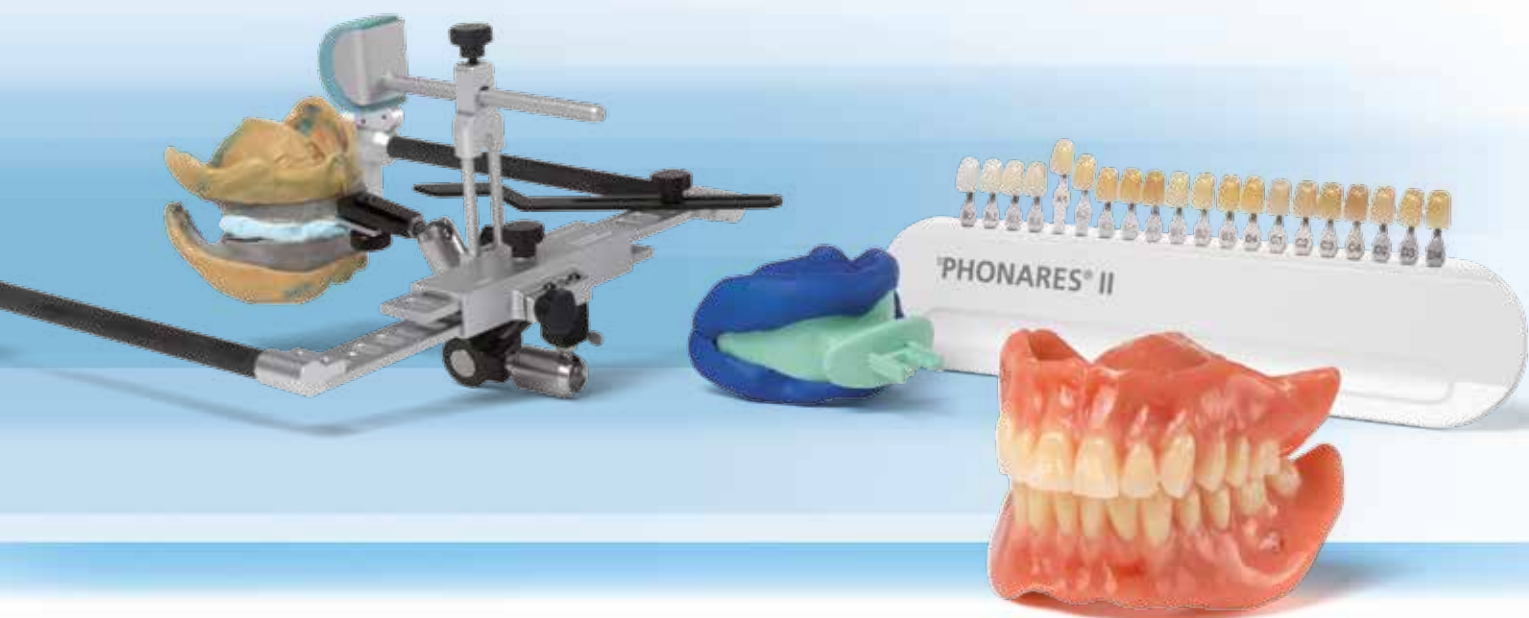

# Removable Denture Prosthetics

Principles according to the BPS® Concept

## Clinical Protocoll



The materials and devices shown in this Protocol are examples. Their availability varies depending on the country and region. For any questions regarding the local availability or use of additional products, please contact your local Ivoclar Vivadent representative or dealer.

**Removable Denture Prosthetics**

Principles according to the BPS® Concept  
Clinical Protocol

1<sup>st</sup> edition

© 2014 Ivoclar Vivadent AG, Schaan

# Table of Contents

Page

- 4 ▶ Introduction
- 5 ▶ Collaboration between clinician and dental technician
- 6 ▶ First appointment
  - Esthetic aspects
  - Clinical history
  - Findings
  - Diagnosis and treatment planning
- 12 ▶ Second appointment
  - Evaluation of vertical relationship and provisional maxillomandibular relations
  - Initial anatomical impression
  - Tray selection
  - Impression-making
- 16 ▶ Third appointment
  - Evaluation of customized trays and provisional occlusal height
  - Functional impression-making
  - Registration of maxillomandibular relations and facebow transfer
  - Alternative method: Hand-guided bite registration
  - Tooth selection
- 27 ▶ Fourth appointment
  - Wax try-in
  - Evaluation in the patient's mouth
  - Shortcomings in the denture wax-up and correction of shortcomings
- 30 ▶ Fifth appointment
  - Final check
- 32 ▶ Continuing care and maintenance
  - Wearing dentures at night
  - Cleaning
  - Post-insertion care
- 33 ▶ References

# Introduction

## Will there still be a need for complete dentures in the future?

Although the efforts undertaken in the field of preventive care have had a sustained impact with the number of edentulous patients having fallen to one per cent among the 35- to 44-year olds and to 22.6 per cent among the 65-year olds<sup>1</sup> in Germany, the answer to this question is nonetheless "Yes".

Studies by Kerschbaum have shown that dentures are worn for a mean period of ten years<sup>2</sup>, in spite of findings by Rarisch, according to which denture replacement is indicated already after seven to eight years<sup>3</sup>. But for all that, 30.5 per cent of patients still wore complete dentures and 28.1 per cent partial dentures in Germany in 2005.<sup>1</sup> These people will need to have their dentures replaced in the next few years.

### Average life expectancy

The 75+ age group has not yet been included in the studies conducted so far, even though the number of patients over the age of 80 is set to increase in the future due to increasing average life expectancies.<sup>4, 5, 6, 7</sup>

The latest data of the DMS IV German Oral Health Study indicate an increase in periodontal disease in the 35- to 44-year-old age group and this increase is particularly severe among the 65- to 74-year olds.

We may therefore expect that many patients will become edentulous in their later life in spite of all the efforts and advances in the field of preventive dental care. This development may harbour additional challenges for clinicians specializing in prosthodontics. The older the patient, the more difficult it is to adapt to new dentures. The reasons for this include changes of the tegument, salivary flow and tissue elasticity as well as

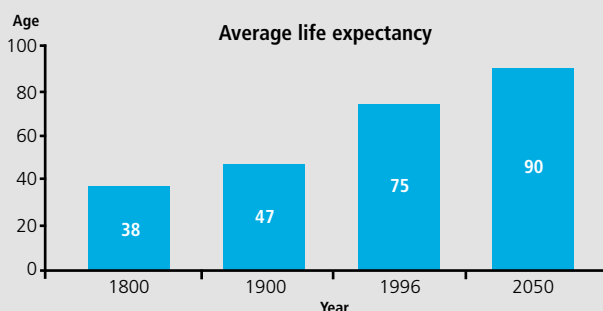
individual cognitive factors, often associated with a lack of mental flexibility to dispense with something familiar. Additionally, old age often brings with it a higher incidence of illnesses, more or less severely affecting the general health of senior patients. This trend is already evident today, as the number of people requiring nursing care is on the rise.

Given the recent advances in implant dentistry, implants can be used today in many cases to provide dental prostheses with additional stability. Yet, this treatment option can often not be pursued because the financial situation or general health of the patient does not permit it. According to the DMS IV study conducted in 2005, 2.6% of senior citizens now wear implant-supported dentures<sup>1</sup>. It should be borne in mind, however, that implant-supported dental prostheses cannot ensure lasting retention without being backed up by a fully fledged prosthetic concept, the ability of the patient to perform adequate oral hygiene and regular follow-up care.

A systematic approach including the patient, clinician and technician will lead to successful results and bring back an element of fun and fascination to complete denture prosthetics. Materials and auxiliaries that allow economically efficient and stress-free working procedures are essential to attain this. BPS® (**B**iofunctional **P**rosthodontic **S**ystem) from Ivoclar Vivadent enables a practical path to help the treatment team achieve functional and esthetic dental prostheses.

Whilst this compendium does not claim to be a comprehensive textbook on complete denture prosthetics, it provides a guideline for creating complete dentures according to the BPS concept.








*Dr Frank Zimmerling*



# ■ Collaboration between clinician and dental technician

The success of the Biofunctional Prosthetic System (BPS®) is based on the close cooperation of dental technician and clinician. Decades of experience have shaped this workflow and continuously optimized it. Applying it leads to functional and esthetic removable dentures with excellent accuracy of fit. Sources of error are eliminated and the results optimized. Satisfied patients and second fitting sessions that are rendered unnecessary speak for themselves.

This manual focuses on the procedures in the dental practice. The procedures in the dental laboratory are described in detail in a separate manual.

<p>▶ Page 6</p> <p><b>Clinical history</b>  <b>Preliminary impressions</b>  <b>Provisional maxillomandibular records</b></p>	
<p><b>Model fabrication</b>  <b>Short model analysis</b>  <b>Customized trays</b>  <b>Intraoral registration</b></p>	
<p>▶ Page 16</p> <p><b>Final impressions</b>  <b>Final maxillomandibular records</b>  <b>Tooth selection</b></p>	
<p><b>Comprehensive model analysis</b>  <b>Model orientation</b>  <b>Tooth setup</b>  <b>Gingiva design</b></p>	
<p>▶ Page 27</p> <p><b>Try-in</b></p>	
<p><b>Completion</b></p>	
<p>▶ Page 30</p> <p><b>Insertion</b>  <b>Continuing care</b></p>	

# ■ First appointment

## Esthetic aspects<sup>8</sup>

Loss of teeth and the ensuing alveolar bone resorption and muscle atrophy lead to facial changes typically associated with ageing. Edentulousness often contributes to an appearance of premature ageing and being edentulous has not only a physiological but also a psychosocial impact on the lives of these patients. Perceptions of ageing are increased by:

- loss of lip support increases the angle between nose and upper lip,
- deepening nose to mouth folds and vertical wrinkles around the lips,
- thinning vermilion border,
- loss of lower facial height,
- protruding chin; increasing pseudoprognathism ("bulldog" look),
- pronounced submental fold.

## Clinical history

First, the reasons for the patient's visit to the dental practice should be established. Sometimes, patients do not always wish a new dental prosthesis but feel under pressure from their spouse or a family member to have their dentures replaced, or, if they are in a care home, the nursing staff or family doctor may have urged them to do so. This may bear the risk that the patient is sceptical or even hostile towards the new prosthesis and may be reluctant to adapt to the unfamiliar new device. It is essential to proceed cautiously in such cases and preferably amend the "old" and familiar prosthesis with the help of appropriate measures. This applies in particular to patients who are mentally or physically impaired because they suffer from dementia, Alzheimer's or Parkinson's disease. In such cases, family members who would like the esthetic appearance of their loved one to be enhanced or family doctors who are hoping that their patient's nutritional status would improve if they had a "new set of teeth" have to be made aware of the fact that removable complete dentures are mainly held in place

by neuromuscular control rather than by a purely mechanical mechanism.

It is also essential to include the patient in the fact-gathering process: what aspects do they like about their current prosthesis and what aspects do they want to be changed? Unrealistic expectations should be put into perspective before the treatment is started: Dentures do generally not smooth out wrinkles and facial lines. Additionally, removable dentures do not offer the same level of retention as fixed tooth replacements. Only after the clinical history and the diagnostic findings have been evaluated can patients be given a reasonably realistic assessment regarding the implementation of their wishes and expectations. This is particularly important if treating patients who keep being unsatisfied with their dentures even if they have already had them replaced several times by different treatment providers.

Advances in the field of denture base materials and artificial teeth have enabled dental professionals to be in a position to meet the increasing esthetic demands of today's society and provide patients with highly esthetic, natural-looking dentures.

People will become toothless at a much later stage in life in the future. With increasing age, the likelihood of suffering from different chronic conditions also increases. Many of the diseases that typically affect old people and the associated medications have a direct or indirect effect on the oral mucous membrane and by extension affect the retention and acceptance of new dentures. For instance, 10 to 15 per cent of people above the age of 65 (and 33 to 48 per cent of people living in old people's homes) suffer from chronic depressions. Many antidepressants affect saliva production. It is also essential to bear in mind that the chances of the new dentures being accepted by the patient are slimmer if the patient is going through a phase of depression.

To provide successful prosthetic treatment, you should not only know the patient's general condition and ability to cope with mental and physical strain, but you should also be aware of

any regular intake of medication. If the patient is suffering from drug-induced xerostomia, as is often the case with the drugs listed in Table 1, it may be possible to change the patient over to a different medication upon discussion with the patient's family doctor.

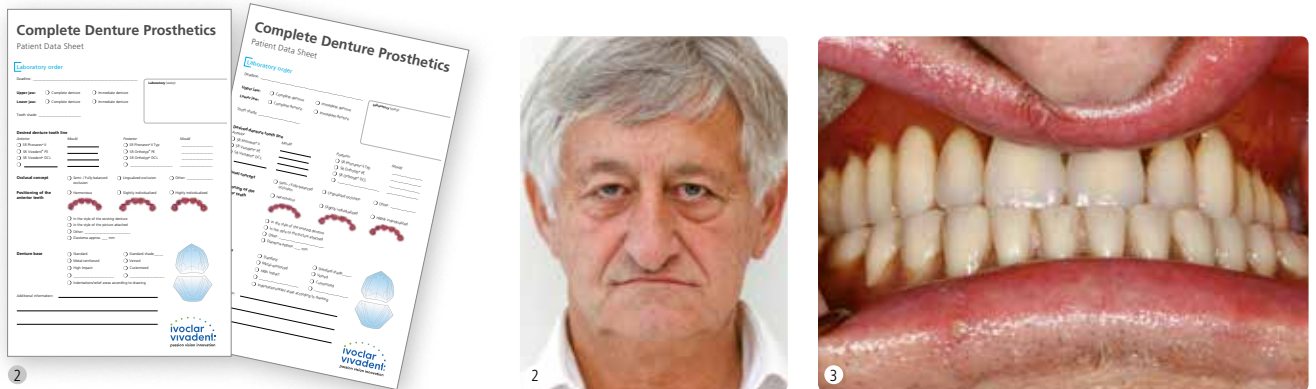**Clinical history checklist:**

- Reason for dental visit
- Wishes/expectations
- General condition/medical history

**Findings**

**Extraoral**

The examination should begin with an extraoral inspection. For those patients who are already wearing dentures, the occlusal height, speech, denture retention and similar aspects are checked for possible shortcomings during the initial consultation. Esthetically critical aspects such as the length and position of anterior teeth, smile line, lack of buccal corridor or midline misalignment are also evaluated (Figs 2 and 3).



Drug class	Examples of brand names
Antidepressants	Saroten®, Lithiofor®, Aurorix®
Antihistamines	Vomex®, Emesan®
Antiparkinson agents	Amantadin PK-Merz®, Akineton®, Adekin®
Antipsychotics	Haldol®, Fluxanol®, Taxilan®, Risperdal®, Leponex®
Tranquilizers	Valium, Tavor®, Tranxilium®, Lexotamil®
Antihypertensive agents	Concor®, Nebilet®, Catapresan®, Beloc®, Nifedipin®
Diuretics	Lasix®, Arelix®, Torem®, Burinex®, Hydromedin®
Muscle relaxants	Musaril®, Sirdalud®, Lioresal®
Centrally acting analgesics	Katalodon®, Tramal®, Dilaudid®, Morphin®, Merck®, Dolantin®, Temgesic®

Table 1



### Intraoral

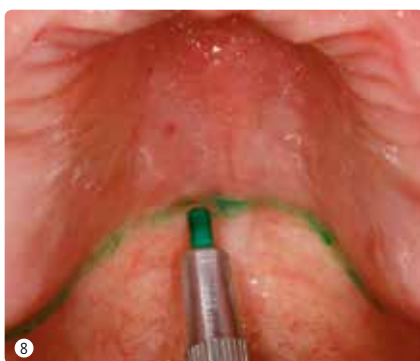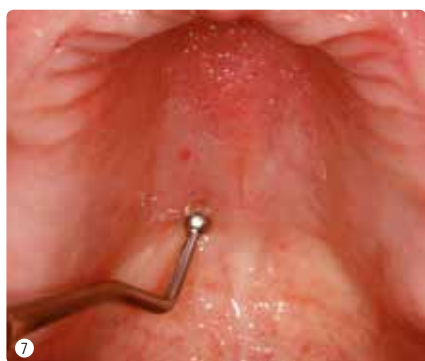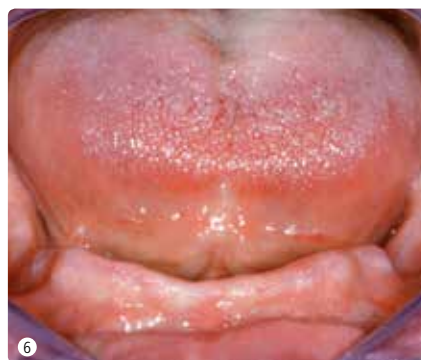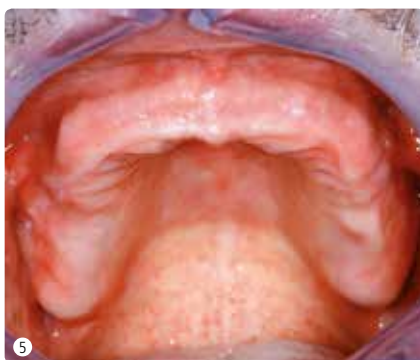
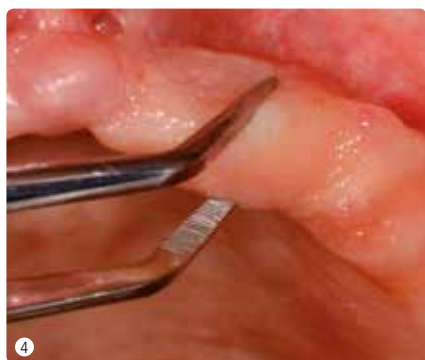The residual ridges play the most important part in complete prosthodontics (Figs 5 and 6). Examine the height and width of the residual ridge and inspect it for possible defects caused by surgical interventions and for areas with excessive fibrous tissue ("flabby ridge") (Fig. 4). Sharp bony residual ridges are painful when lightly pressed and may result in pressure spots. They should be smoothed out surgically before the prosthetic treatment is commenced. Similarly, a prominent torus palatinus or mandibularis may have an adverse effect on the retention of the denture and may need to be removed, if necessary.

In the upper jaw, prominent tuberosities are beneficial for the stability of the denture. In the lower jaw, alveolar bone atrophy may be four times as severe as in the upper jaw<sup>10</sup>; in some cases, this may lead to a "negative" ridge and may even result in exposure of the nervus mentalis. Since in this case the pressure exerted on the nerve by the denture may cause severe chronic pain, this area should be checked for pain by palpitation with a spherical condenser. Upon completion of the denture, the load on this area should be relieved by grinding. Surgical intervention may be considered in severe cases if large parts of the nerve are exposed.

The condition of the mucous membrane is similarly important as the alveolar bone support. The alveolar processes should be covered with attached mucous membrane to ensure a favourable prognosis. Denture retention may be adversely affected if the lingual and buccal frenula are attached close to the crest of the ridge or if the alveolar ridge is extensively covered with loose mucous membrane. If the floor of the mouth is flat, the stability of mandibular dentures may be impaired. The floor of the mouth in the sublingual anterior region should be soft when pressing on it; an ossification in this area would be disadvantageous.

In the maxilla, the denture is mainly held in place by the atmospheric pressure, or suction, created when the denture base is pressed against the mucous membrane. A complete border seal is a basic requirement to achieve retention by suction. In the dorsal area, the palatal seal is created at the junction between the hard and soft palates as the posterior surfaces of the denture base compress the mucous membrane in this soft area, preventing air entry between the denture and soft palate.

The transition between the hard and soft palates can be palpated with a round condenser and/or visualized by watching





the beginning of motion in the soft palate when the patient says a long "ah" (Figs 7 and 8). Another technique to locate this line is to ask patients to blow air through their nose while their nostrils are gently pinched closed, causing the soft palate to visibly extend towards the anterior.

In some cases, the Ah line is well defined, in other cases a wide "vibration zone" can be seen; the latter is considered to be more favourable for achieving a complete seal.

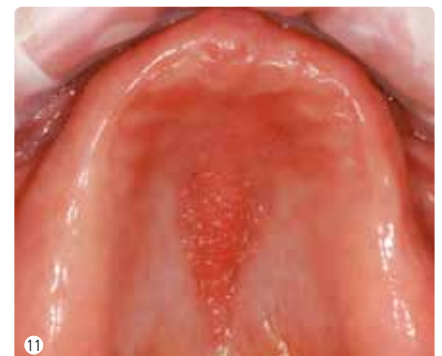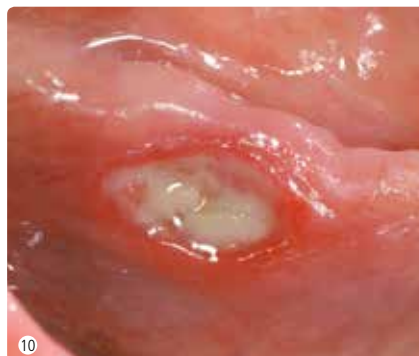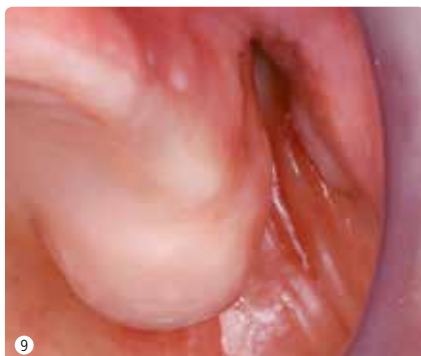During palpitation of the vibration zone, it is helpful to note if the patient has problems with gagging. A hypersensitive gag reflex may not only complicate impression-taking but also affect the palatal design of the denture and therefore impact on denture retention. Patients with a severe gag reflex may not tolerate any palatal coverage. In these cases, implant-retained palateless dental prostheses are required.

Low attachment of the buccal mucosa and extensive buccal pockets lateral to the maxillary tuberosities have a beneficial effect on denture retention. This area should be appropriately filled when designing the functional borders of the denture to achieve a complete seal<sup>8</sup> (Fig. 9).

As a general rule, fabrication of a new dental prosthesis or improvement of an existing device should only be performed once the oral mucous membrane is in a healthy condition. Sore spots, inflammations, extraction wounds and/or candida infections must be treated first (Figs 10 and 11). If the existing

prosthetic device is causing irritation and inflammation, it should be adjusted by grinding and, if necessary, by relining it with a resilient material. Complete removal of the dentures for a few days would be the best method to help the tissues heal quickly, but patients rarely accept this measure for understandable reasons. Additional application of a chlorhexidine gel or rinsing solution can facilitate the healing process. Irritation fibromas that do not disappear by themselves after the interferences causing them have been eliminated should be surgically removed if they impair denture retention. It does not seem to make sense to remove a flabby ridge, which often occurs in patients who have residual teeth in the lower anterior region and wear a complete maxillary denture. Removal would only result in an unduly flat residual ridge, leaving the denture more vulnerable to horizontal forces. If the natural residual dentition remains in the oral cavity, the pressure exerted on the remaining alveolar bone will lead to another flabby ridge. In this case, it would be an advantage to use special techniques to create a pressure-free impression of the mobile areas, if possible.

Salivary flow also plays an important part in denture retention. Together with the mucous membrane, saliva, which ideally should be of a mucous consistency, aids in holding the denture to the oral tissues through capillary action. The seal created in the process results in atmospheric pressure and contributes to the suction effect of the denture base. In addition, oral tissues that are well moistened are less susceptible to mechanical injury (e.g. pressure spots).<sup>8</sup>



### Function

If the patient complains about pain of the temporomandibular joints and/or muscles during chewing or if movement of the mandible is impaired, a functional assessment and therapy may be indicated. If the patient is complaint-free, the focus is placed on assessing the most fundamental functional parameters.

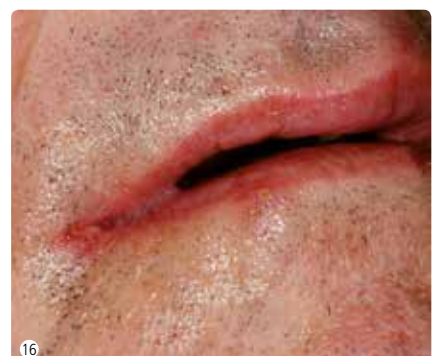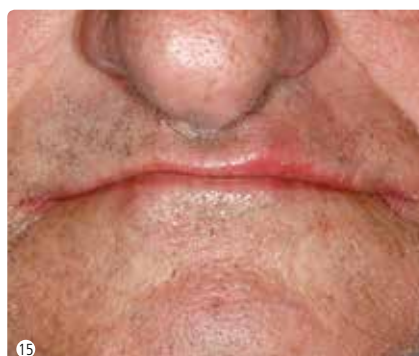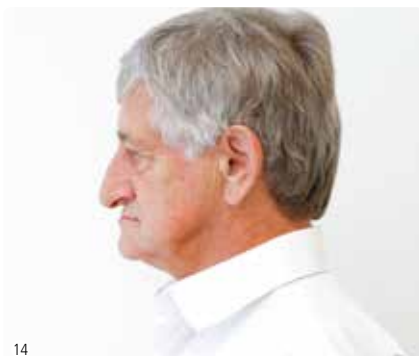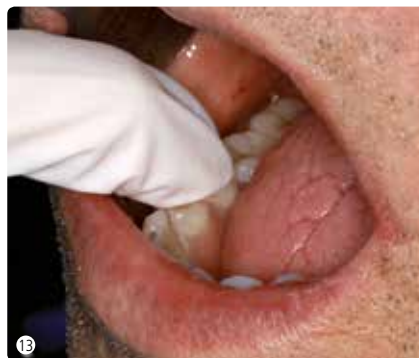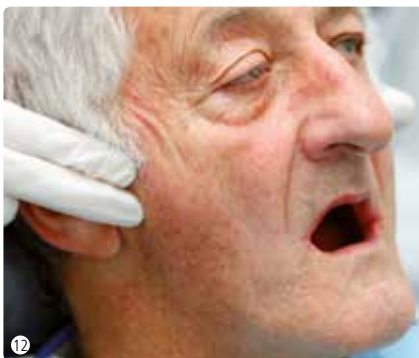Palpate the large masticatory muscles, searching for areas of tenderness and indurations; examine the temporomandibular joints by lightly pressing on them. Lightly pull or press on the mandibular angles to ascertain if the jaws are free of pain. Check for joint sounds (clicking, scraping) and deviations upon opening and closing (Fig. 12).

To evaluate the functional acceptability of existing dentures, their positional stability is checked first. In the upper jaw, the denture should not come loose when pushing against the dental arches. In the lower jaw, a suction effect is rarely present. However, mandibular dentures should stay firmly on the alveolar ridge when pressure is applied onto the anterior or posterior teeth and they should not shift to the side too easily (Fig. 13).

To evaluate the vertical dimension at occlusion and at rest, the patient should be seated upright or standing. If seated, the

patient should be in a relaxed position with an upright head. The legs should not be crossed. Mark two points, one at the tip of the nose and one at the tip of the chin, using a coloured pen. Subsequently, patients should be asked to wet their lips with their tongue several times and then relax their lower jaw muscles. By humming "mmh" or slowly and gently breathing out through loosely closed lips, the muscles relax. Now measure the distance between the two selected points. Patients who wear dentures are asked to occlude. Consequently, the distance can be measured. The difference between the vertical dimension at occlusion and the vertical dimension at rest should be two to three millimetres. Instead of measuring the vertical dimension at rest, it can also be determined by estimating the distance between the maxillary and mandibular teeth. For this purpose, gently open the lips and corners of the mouth using two mouth mirrors while the patient is relaxed.

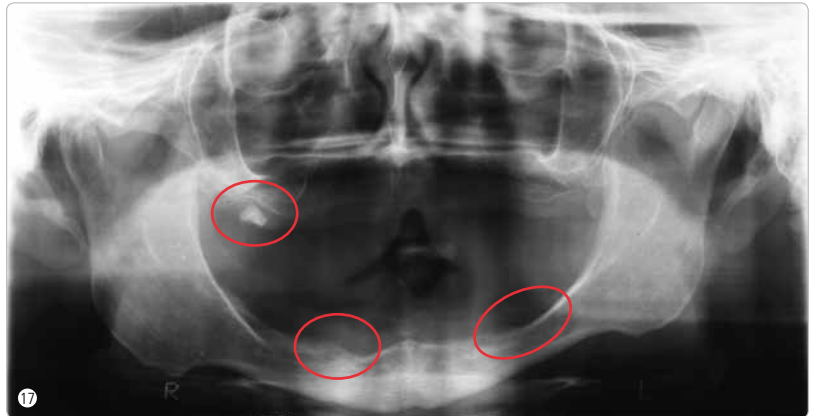
Signs indicating a decreased vertical dimension can often be noted already at the initial extraoral examination. These signs include angular cheilitis (Fig. 16), hardly visible vermilion border (Fig. 15) or a narrow nasolabial angle (Fig. 14). An increased vertical dimension causes the lips to look strained (mouth appears "too full") and the dentures produce a clicking noise during speech.



### Radiological examination

An orthopantomogram is recommended for assessing the oral situation prior to fabricating complete dentures. A radiological evaluation allows pathological conditions such as cysts, root caries, impacted teeth, etc. to be assessed prior to commencing denture fabrication. If necessary, appropriate surgical measures can be taken (Fig. 17).

Additionally, the location of the mental foramina and the course of the inferior alveolar nerve can be assessed on the radiograph.<sup>17</sup> To prevent chronic pain caused by pressure exerted on exposed nerves, atrophy-induced exposure of nerves should be considered from the beginning of planning the prosthetic device.<sup>8</sup>



### Diagnosis and treatment planning

After the diagnostic process has been completed, the patient is given a diagnosis and the treatment plan is discussed, providing answers to the following questions:

- Is any preprosthetic surgery needed?
- New denture fabrication or modification of existing dentures?
- Any need for additional support by implants?
- Treatment sequence and length of time to complete treatment
- Estimate of cost for the treatment

## ■ Second appointment

### Evaluation of vertical relationship and provisional maxillomandibular relations

If the occlusal height of the existing prosthetic device has been found to be adequate it can be incorporated into the new dentures. If deviations have been identified, the height should be re-defined.

For this purpose, the patient should be in an upright position (either seated or standing). A small dot is marked on the tip of the nose and on the tip of the chin. Patients are asked to relax, moisten their lips several times and hum "mmmh" or gently breathe out air through the lips to relax the muscles and the distance between the marked dots is recorded using a sliding gauge. The distance measured between the two dots is reduced by three millimetres of freeway space on the gauge to establish a preliminary occlusal height (Fig. 18).

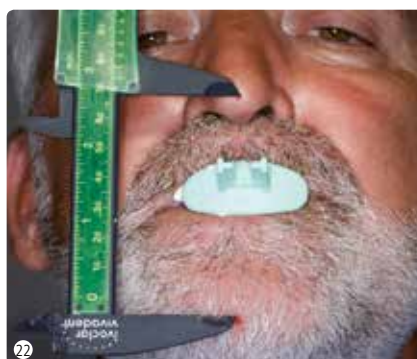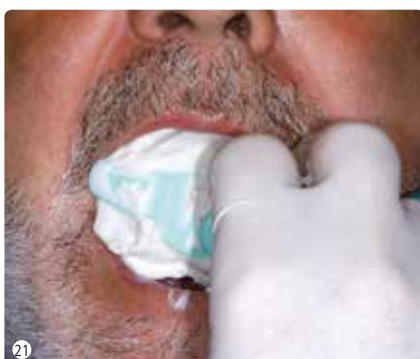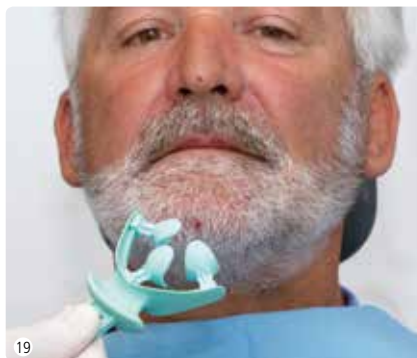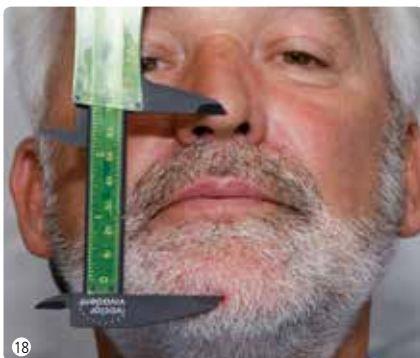The provisional occlusal height is determined with the help of a Centric Tray, similar to the dual impression technique. Either use pre-measured alginate or silicone putty for impression-making (Fig. 19).

Prior to taking the impression, check if the patients are capable of closing their mouth enough to reach the previously established occlusal height without difficulty when the Centric Tray is placed in the oral cavity. Mixed impression material is filled into the upper and lower part of the Centric Tray and given a slightly convex curvature under cold running water while the area of the tongue is left uncovered (Fig. 20).

The loaded tray can now be inserted into the patient's mouth and seated on the mandible (Fig. 21).

Patients are asked to slowly close their mouth until the defined occlusal height is reached while the sliding gauge is held against their face. Subsequently, ask the patients to swallow and to keep the mouth still until the material has completely set (Fig. 22).

As an option, essential information on the arbitrary skull-related position of the temporomandibular joint may be gathered and passed on to the technician already at this stage by mounting an UTS 3D transferbow.





## Initial anatomical impression

The objective of the anatomical impression is to record all the oral structures fundamental to denture retention and stability. Aim at creating a slightly overextended impression for this purpose. If important details are missing, denture retention may be adversely affected. We recommend using specially designed pre-fabricated impression trays to be able to record all relevant areas of the edentulous jaw while the impression is optimally supported.<sup>8</sup>

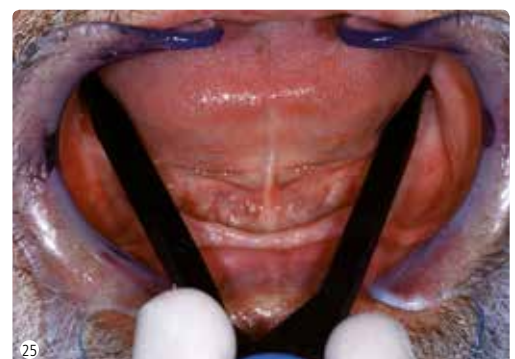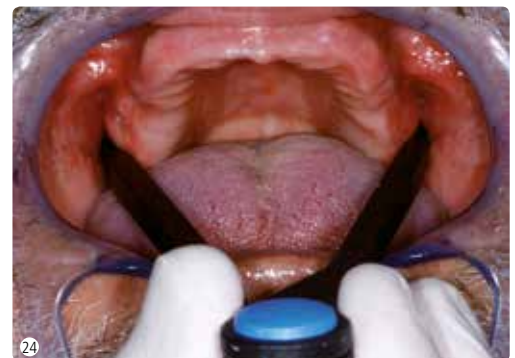Accu-Dent® has been proven to be suitable for this indication. This impression system is available in a range of tray sizes and moulds including a two-component material system based on alginate (Fig. 23).

## Tray selection

Tray selection is accomplished with the help of callipers. Position the legs of the callipers on the buccal sides of the maxillary tuberosities to determine the size for the upper tray (Fig. 24).

In the mandible, measure the distance between the mandibular alveolar tubercles (retromolar pads) (Fig. 25).

Select a tray that is at least five millimetres wider than the width recorded with the callipers. To be able to obtain an accurate impression of the distal rise even in poor residual ridges, the Accu Tray range contains trays with an especially designed exaggerated distal rise.



## Impression-making

To create an overextended anatomical impression, a pre-measured solid impression material that is not displaced by the cheeks, lips or tongue or "runs off" the tray is required. However, this type of material is prone to producing voids if a high palate or deep pockets in the vicinity of the tuberosities are present, as it does not easily adapt to these areas. This problem may be resolved by utilizing pre-dosed Accu-Gel, which consists of two interfacing impression materials, one with a flowable low viscosity and the other with a high viscosity for use in the dual-phase impression technique.

Both materials are prepared and then the orange material is backloaded into the syringe (Fig. 26) and the white heavy material is loaded onto the tray. The surface is smoothed out under running water and an anterior rim that thins out towards the back is created (Fig. 27).

A line of low-viscosity Syringe Gel is expressed into the mucobuccal fold from the maxillary tuberosity forward to the midline while the cheek and lips are retracted. When the upper lip frenulum is reached, the syringe is placed at the back of the other side and the procedure is repeated on this side too. After

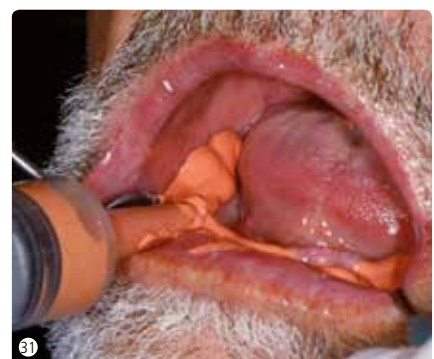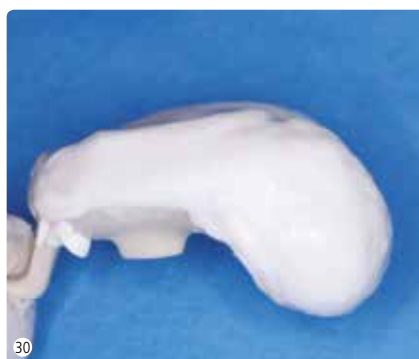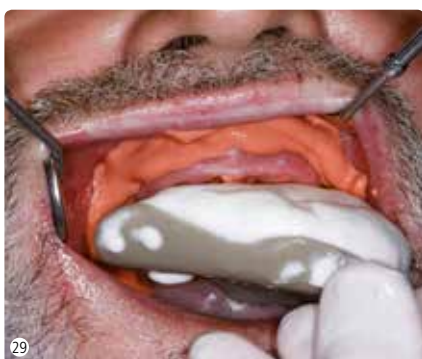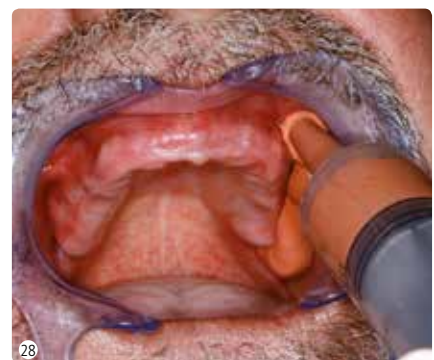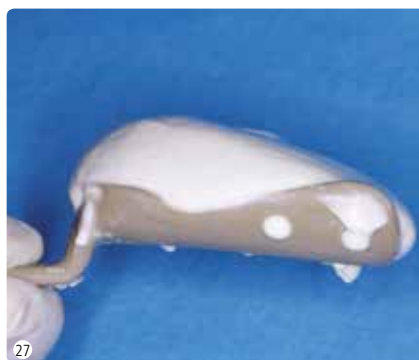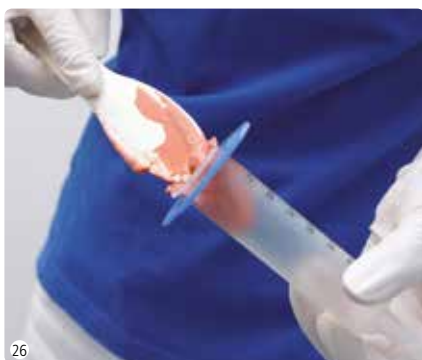that, a final portion of material is applied into the anterior vault of the palate (Fig. 28).

Next, the loaded tray is inserted. Best practice is to adapt the tray in the front first and then rotate the tray upwards in the back (Fig. 29). If material appears at the distal edge of the tray, hold the tray in position until the material has completely set without applying pressure.

Define the dorsal border (Ah line) as described on page 8 and mark it with a suitable copying pen. To transfer the line to the impression material, seat the impression again in the oral cavity and press it into position for a short while. If the line is carved into the alginate with a scalpel, it will remain visible on the model even if the ink of the pen has become faint after exposure to disinfectant.

When loading the mandibular tray, the white material is applied in a bulge in the dorsal area of the mandibular alveolar tuberosities as a large amount of material is required in these areas. Accurate reproduction of the retromolar trigon plays a decisive role in the stability of lower dentures (Fig. 30).

A line of orange Syringe Gel is again pressed into the vestibule from the retromolar pad forward to the midline on both sides,



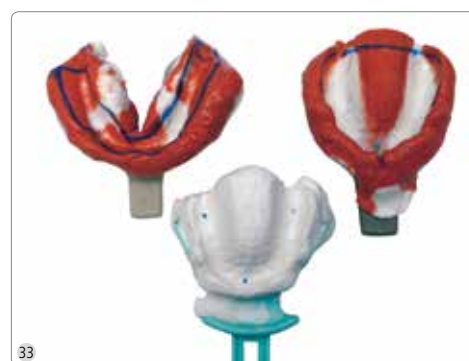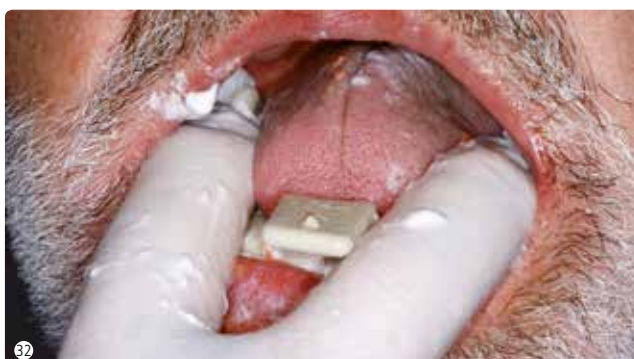while the cheeks and lips are retracted. It is not mandatory to place low viscosity Syringe Gel into the lingual vestibules. However, if any material is left in the syringe, it may be applied into the sublingual area (Fig. 31).

The tray is rotated into place and adapted beginning from the anterior side. Then, the tray is held in position with two fingers and the patient is asked to push the tongue forward and to move it to the left and right as far as possible. After that, the material should be allowed to set without any further movement with the mouth slightly closed (Fig. 32).

Ideally, the following structures should be reproduced on the impression (Fig. 33):

- complete extension of alveolar ridges,
- maxillary tuberosities including the hamular notches in the upper jaw,
- retromolar pads in the lower jaw,
- mylohyoid ridges in the lower jaw,
- vestibulum with transition between movable and immovable mucous membrane, particularly in deep areas such as pockets (if present) adjacent to the tuberosities
- full height and extension of the hard palate up and into the soft palate.<sup>8</sup>

If any of these structures has not been clearly captured, the impression should be repeated. Three-point support is sufficient for the subsequent mounting of the models, if a provisional record of the maxillomandibular relations has been taken with the Centric Tray.





## ■ Third appointment

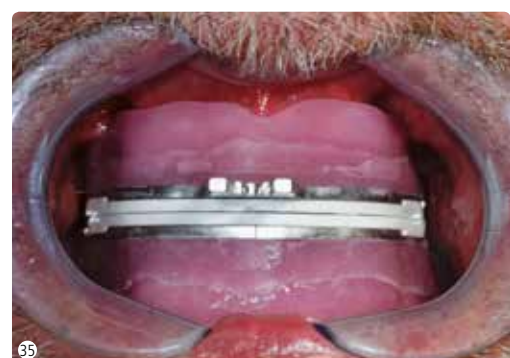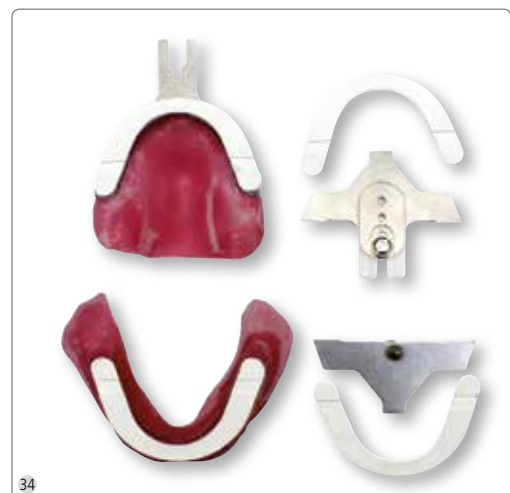- Functional impression-making
- Final registration of maxillomandibular relations
- Facebow transfer, if necessary
- Selection of tooth shade and shape

### Evaluation of customized trays and provisional occlusal height

The technician prepares a customized impression tray including wax and/or plastic occlusal rims or a Gnathometer M for the combined functional impression-making and registration of maxillomandibular relations appointment.

Check the trays for sharp edges or possible interfering spots and try them in on the patient. Check the extension of the tray margins and make sure that the labial and buccal frenula are free. The dorsal extension of the maxillary tray should correspond with the marking on the initial impression and provide complete coverage of the hard palate. If the tray extends too far back, it may cause gagging and should be shortened. If the tray is too short, it may be lengthened with compound material. The vestibular margins should end approx. 2 millimetres short of the deepest point of the mucolabial fold and must never be overextended. If the cheeks or lips are pulled, the tray should not rise from the mucous membrane. In the mandible, the stability of the tray during movements of the tongue is checked.

The patient must not feel any pain even if occluding onto the rims. If not, the registration or functional impression may be negatively affected because the patient will use compensating movements to avoid the pain. Remove interfering spots by grinding. The white plastic rims should be parallel to and flush with each other (Fig. 35).



## Functional impression-making

### Purpose of a functional impression:

1. To create an accurate reproduction of the tegument to achieve a hermetic internal seal
2. To determine the extensions of the denture borders, taking into account the tongue and perioral musculature; to achieve a peripheral seal by ensuring a gap-free adaptation to the cheek and lip
3. In the maxilla: Visualization of the Ah line/vibrating line to achieve a tight posterior seal

A healthy mucous membrane free of inflammation and pressure ulcers or other changes is prerequisite to obtaining a successful impression.

### Impression materials

A variety of materials are used for impression-making. Mostly thermoplastic, polyether or silicone materials are used for border moulding. Thermoplastic impression materials are, *lege artis*, applied in several steps and therefore involve a time-consuming application procedure that takes some getting used to. The consistency of polyether-based materials is usually too soft so that they run off the tray. Experience has shown that silicone, putty and heavy-body materials are ideally suited for impression-making. These materials feature a stable consistency and a flexible setting time, depending on whether a fast or regular material is used.

Impressions of the denture base are usually taken with zinc oxide pastes, polyether materials or silicones; alginates are also used in some countries. Zinc oxide pastes provide highly accurate impressions and easily adapt to the oral structures if light pressure is exerted. The disadvantage of zinc oxide

impressions is, however, that they are difficult to disinfect since they expand if stored in water. Additionally, they are difficult to manipulate because of their sticky consistency and low viscosity. The material is also inconvenient for patients because it does not taste pleasant and it is difficult to remove from the lips and face.

Excellent results can, however, be achieved with the low-viscosity Virtual® Light Body silicone impression material. Furthermore, any necessary adjustments can be easily achieved with Virtual Extra Light Body. This material accurately captures the details of the oral tissues, has a pleasant flavour and is easy to remove and disinfect. Virtual Heavy Body is recommended for border moulding. The tray may be coated with tray adhesive to strengthen the bond to the impression material.

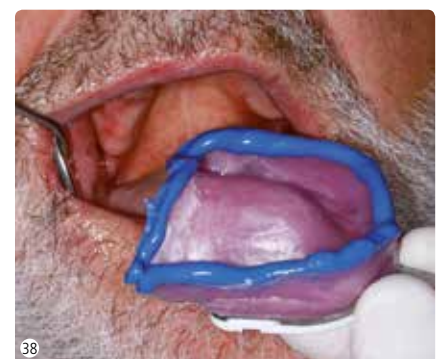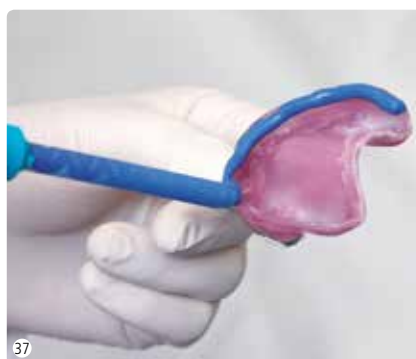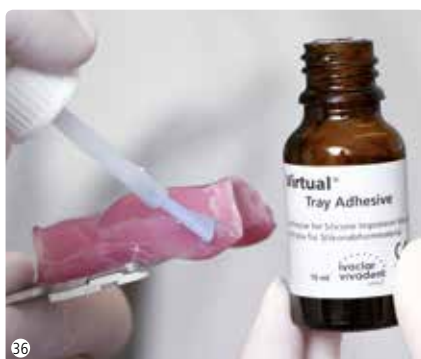### Impression-making

After the trays are examined and adjusted as necessary, they are rinsed and dried. If the closed-mouth technique is used, it is advisable to take the maxillary impression first since by the time the mandibular impression is taken, the suction effect will hold the maxillary impression firmly in place.

Coat the borders and the area of the Ah line (vibrating line) with adhesive varnish and dry with a gentle stream of air (Fig. 36).

Dispense Virtual Heavy Body directly from the double-barrel syringe to the ridges of the tray; make sure to apply sufficient quantities of material particularly if deep pockets in the retro-molar region are present (Fig. 37).

Retract the cheek and lips when inserting the tray to prevent the impression material from being wiped off the tray (Fig. 38).



After positioning the tray, hold it in place with your index finger. Ask the patient to suck on your index finger to activate the cheek's muscles.

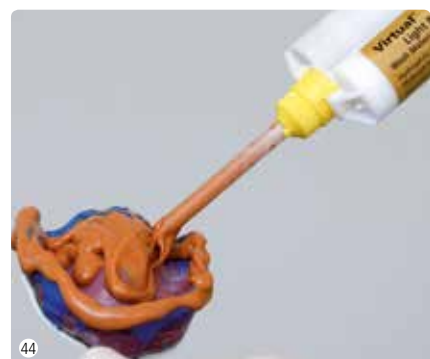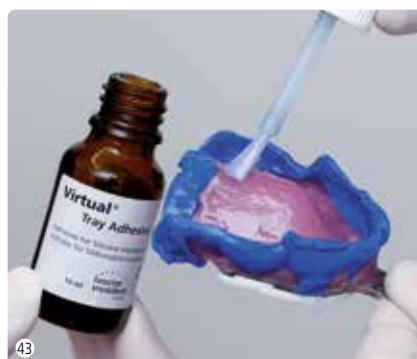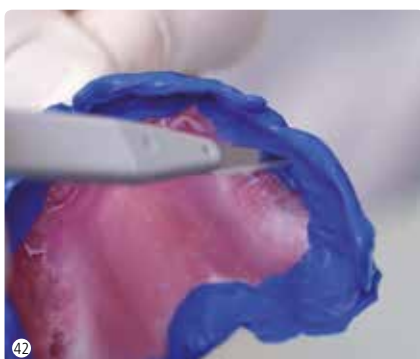
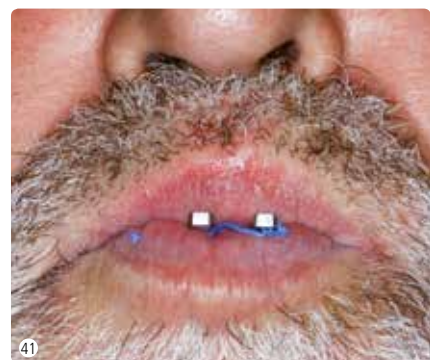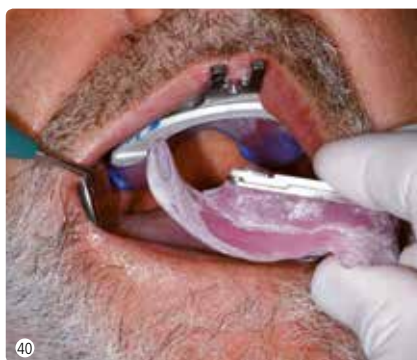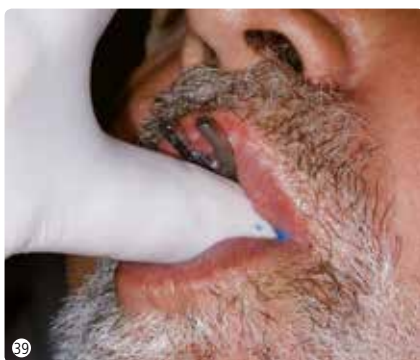Then, the patient should relax the muscles and repeat the procedure. Next, the patient is asked to move the open mandible to the left and right two to three times. Now, insert the mandibular tray and ask the patient to close; the occlusal rims, or placeholder plates, should sit flush on top of each other when the patient occludes on them (Fig. 40).

With the mouth closed, patients are now asked to alternately purse their lips and smile ("kiss and smile") several times while applying light masticatory pressure. Prior to taking the impression, explain to the patient what movements they are going to perform and for what reason and encourage them to do them to their maximum to activate the muscles as much as possible (Fig. 41). Depending on the principles applied, additional and/or other functional movements may be performed.

Once the material is set, the tray is removed and the peripheral outline of the impression examined. The tray should provide a suction effect at this stage already and the margins should be uninterrupted and free of bubbles and voids. If the plastic compound of the tray material has pushed through in some parts, reduce it by grinding.

On the inside of the tray, remove the pressed material to approximately two millimetres using a scalpel (Fig. 42), then rinse the tray again with water, dry it and apply a coating of adhesive (Fig. 43).

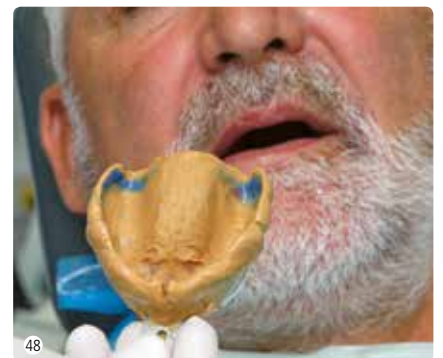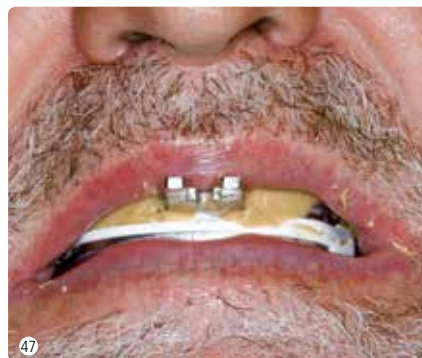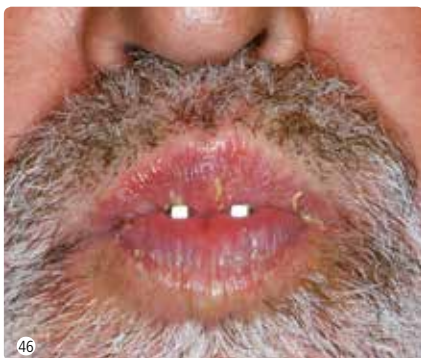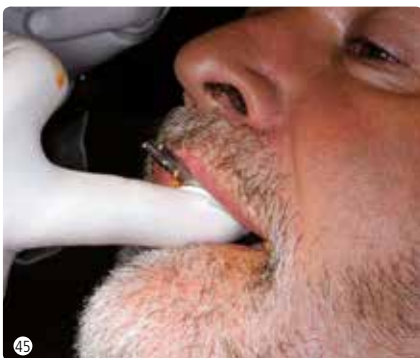Next, load the ridges and palatal surface with Virtual Light Body and spread the material to a thin layer using a spatula (Fig. 44).



Seat the tray into position in the patient's mouth, applying light pressure. Remove surplus material that has escaped at the dorsal edge with a mouth mirror. Now ask the patient again to suck on your index finger and then ask to move the lower jaw to the left and right (Fig. 45).

After removing any surplus material from the dorsal edge of the tray, seat the mandibular tray. The patient closes and again performs the functional movements ("kissing" and "smiling") while applying light masticatory pressure (Figs 46 and 47).

Once the material is set, remove and inspect the trays. Now, a very clear suction effect should be present. If the result is not satisfactory or if small voids are visible in the material, Virtual Extra Light Body may be used to apply corrections to selected areas or to coat the entire impression with a thin (!) layer of material. This "corrective impression" is performed in the same way as above.





Mandibular impression-making follows a similar procedure as described above. After the tray ridges have been coated with adhesive varnish and loaded with Virtual Heavy Body, the tray is rotated into position and held in position in the area of the premolars using two fingers.

Instruct patients to stick their tongue out to their maximum and to move it to the left and right several times. Under no circumstances should the tray rise from the tegument while these movements are being performed! (Figs 49 and 50).

Next, the maxillary impression is seated. The patient occludes; the rims should lie parallel on top of each other. The muscles are again activated by smiling and pursing the lips.

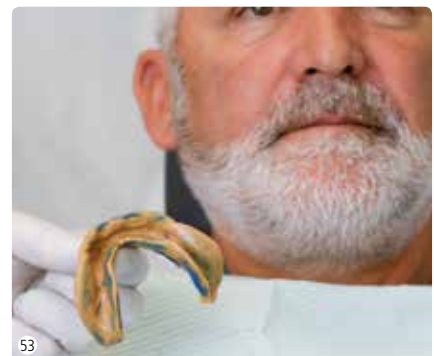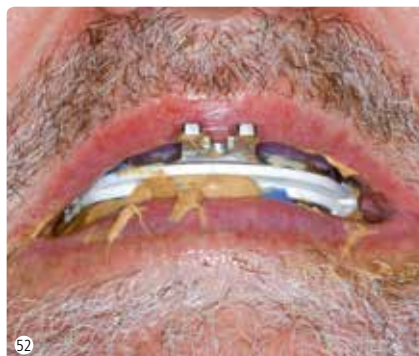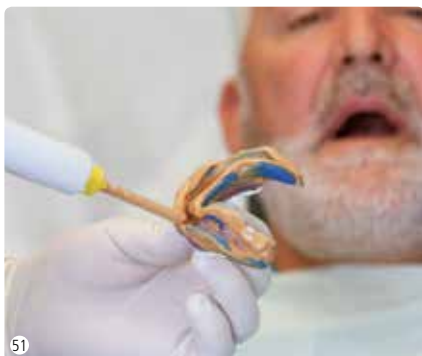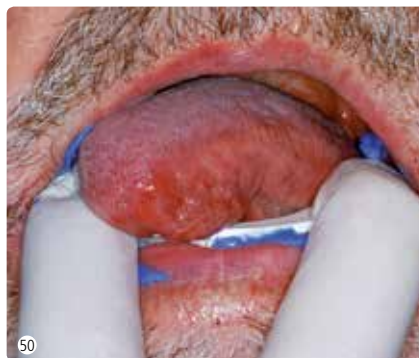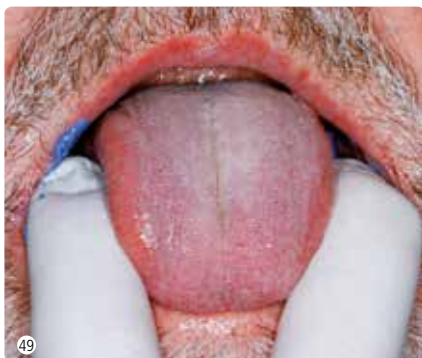Once the material is set, remove the tray and examine the impression. As for the maxillary impression, again trim the pressed material on the inside of the tray to a thickness of approximately two millimetres. Removing material can be very difficult if a narrow residual ridge is present. In such cases, leave the material and apply a coating of Virtual Light Body on top of it.

After applying Virtual Light Body, the impression is taken in the same way as described above for the impression-making of the functional margins (Figs 51 and 52).

Any necessary corrections are performed with Virtual Extra Light Body.

An accurate impression should satisfy the following criteria:

- tidy, uninterrupted functional border,
- surface devoid of bubbles and voids,
- no pushed-through tray material,
- clearly observable suction effect in the maxilla,
- stable mandibular position, preferably with suction effect. (Fig. 53)



## Registration of maxillomandibular relations and facebow transfer

### Gothic arch tracing

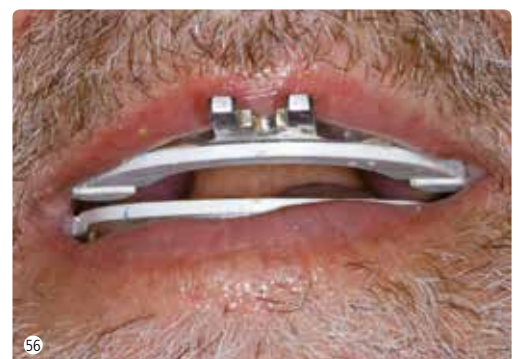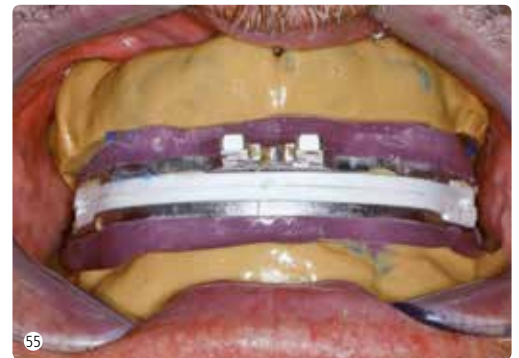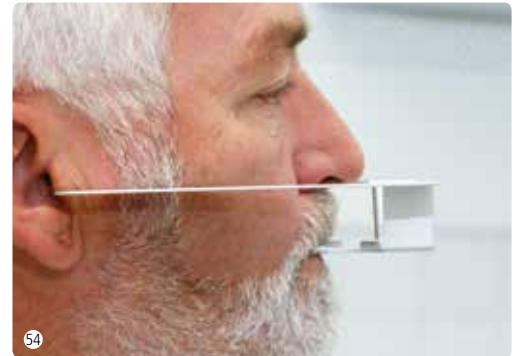In the laboratory, the technician may mount the Gnathometer M on the impression tray/registration plates in accordance with the corresponding requirements to facilitate Gothic arch recording. The plates should be positioned at the height of the occlusal plane, reflecting the previously established provisional occlusal height.

An occlusal plane plate (Fox plate) is placed on the maxillary wax rim to confirm that the maxillary occlusal plane parallels the inter-pupillary line (from the anterior) and Camper's plane (sagittally). Any adjustments may be noted down in a numerical value (+/- mm) on the model and taken into account when the model is mounted. To assess the need for adjustment, the distance between the occlusal plane plate and the centre of the tragus is measured (Fig. 54).

When the registration aids are tried in, the white plastic spacers should rest on each other in parallel position (Fig. 55). Confirm the stability of the functional impression by applying pressure to the impression tray in the region of the molars and anteriors. This method helps to ensure that the mandibular impression in particular cannot be displaced horizontally.

Make sure that the upper and lower tray do not touch dorsally when the patient performs the maximum range of excursive movements. Remove interfering impression material. Remove interfering plastic material by grinding.

Given the stable position of the Gnathometer M, the occlusal height can be verified with a phonetic test. Ask the patient to e.g. count up from 60 to 70, and, if necessary, to count backwards. In most cases, the dentist can obtain an accurate impression of whether the given vertical dimension is appropriate for the patient already at this stage. Ask the patient to assume the vertical dimension at rest position as described above. To check the interocclusal clearance of two to three millimetres, the lips may be gently pushed apart with two mouth mirrors. The freeway space can be easily assessed against the parallel aligned white plates and the dark oral cavity (Fig. 56). Additionally, the clearance can be measured with a sliding gauge.

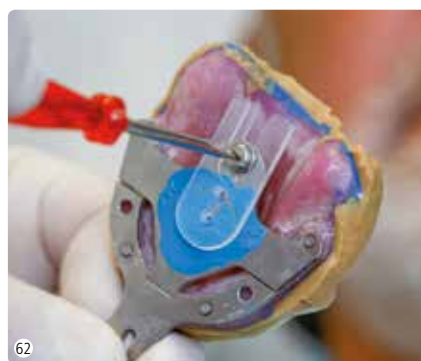
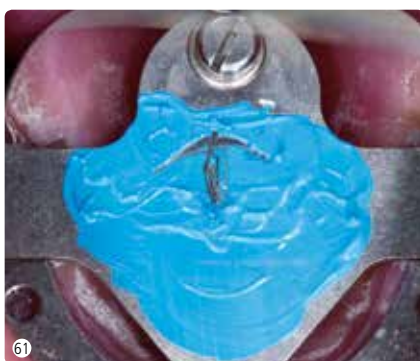
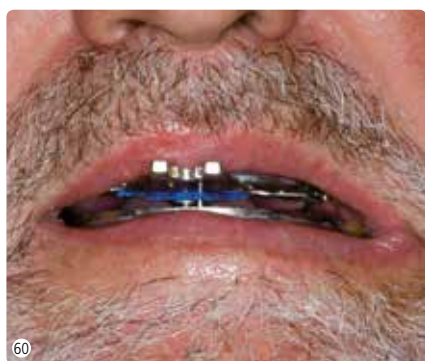
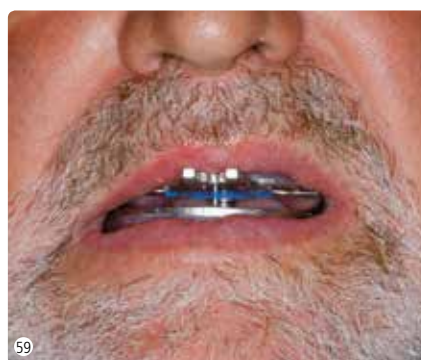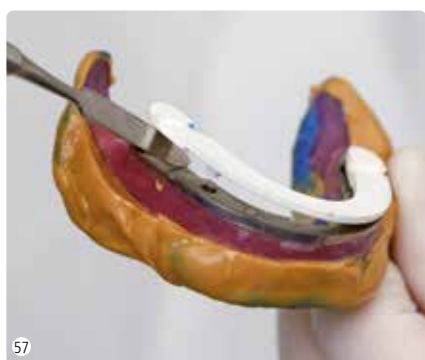If the vertical dimension is too high, remove one or both plates (each of which is two millimetres thick) and assess the phonetics again at the reduced height. Precise adjustment will be performed with the help of the support pin at a later stage – one rotation, or wind, of the thread equals an adjustment in vertical height of one millimetre. The thread is locked in position with a drop of wax. If the vertical dimension is appropriate, the plates are replaced with a registration plate coated with marking material in the upper jaw and with a registration pin in the lower jaw (Figs 57 and 58).

After the registration plates have been inserted, patients are asked to swallow and then close their mouth. Next, they are instructed to bring their mandible slowly forward to their maximum and then bring it back. Patients who tend to open their mouth while performing these movements may be supported by lightly holding the back of the hand under their chin to ensure that contact with the registration plate is maintained at all times. However, the movements must NOT be actively guided. The movements are repeated three times.

Next, instruct the patient to perform three movements to the left and three movements to the right. Prior to each change in direction, the patient is asked to open, swallow and close (Figs 59 and 60).

Ideally, a well-defined Gothic arch record is obtained, allowing the centric relation at the tip of the arrowhead to be fixed with a Plexiglas plate (Figs 61 and 62).





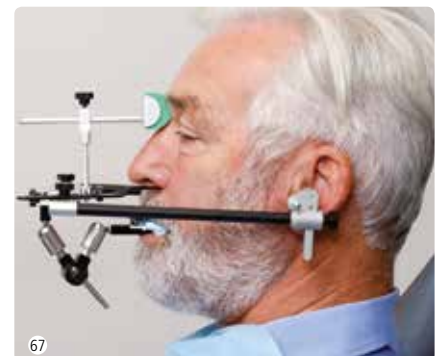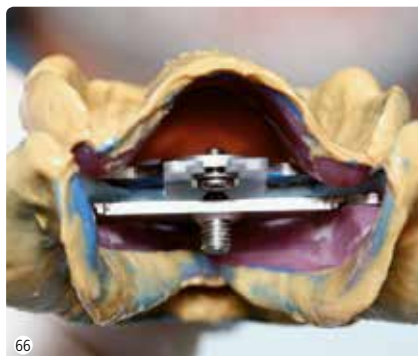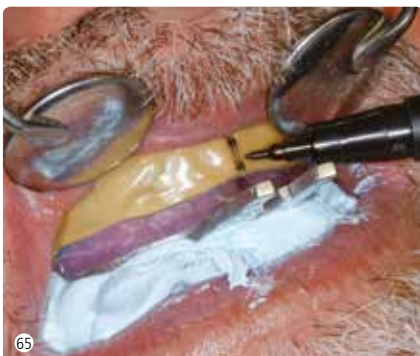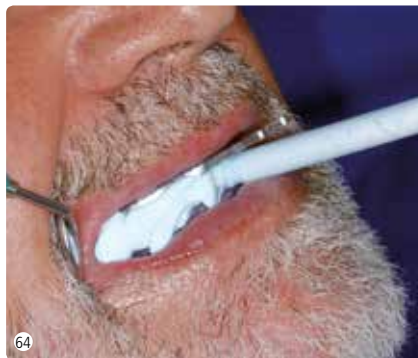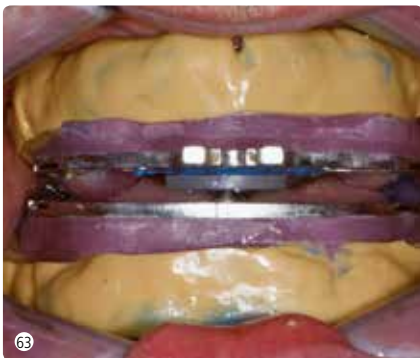After the registration plates have been reinserted, the patient is asked to glide into the established centric position several times without help, some patients will require several attempts to become used to this (Fig. 63).

In this way, the models may be mounted on the articulator directly with the help of the UTS 3D transferbow. Alternatively, arbitrary skull-related articulator mounting by means of a 3D registration joint may be used.

A hard-setting addition silicone, e.g. Virtual CADbite (32 Shore D) is suitable for fixing the bite record. The material is injected into the spaces between the registration aids while the support pin is engaged and the patient's mouth is in a closed position (Figs 64 and 66).

Next, the information relevant to the technician is marked on the record. These data include the maxillary midline, which should correspond with the centre of the philtrum, the cuspid line (interalar width of the nasal base) and smile line (Fig. 65). This can be performed before or after immobilizing the record.

Next, the UTS 3D transferbow can be mounted in accordance with the reference planes (preferably Camper's plane). The UTS adapter on the Gnathometer M registration plate facilitates this step (Fig. 67).



## Alternative method: Hand-guided bite registration

If a hand-guided bite-taking technique is used, the lower occlusal rim should be made of plastic and the upper rim of stable wax. In the region of the molars, the lower plastic rim is provided with retentions by preparing boxes with undercuts using a grinder. The occlusal rims should terminate at the dorsal third of the tray (Fig. 68).

Functional impression-making is carried out as described above. Evaluate the stability of the impressions by applying pressure on the anterior and posterior region. Next, check if the vertical dimension determined by the occlusal rims corresponds with the previously established provisional occlusal height by measuring the vertical dimension at rest and the vertical dimension at occlusion (approx. three millimetres of difference between the two positions) and by checking the patient's phonetics.

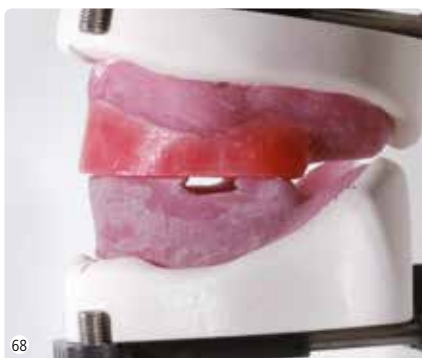Confirm that the rims run parallel to the inter-pupillary line and Camper's plane by means of an occlusal plane plate (Fox plate). The tray should not move or tilt when the patient bites down. Normally, the correct occlusal height is present if the provisional

maxillomandibular relations have been recorded correctly with the Centric Tray. The upper and lower rim should rest flush on top of each other. If this is not the case, adjust the occlusal height of the maxillary rim by adding or removing wax.

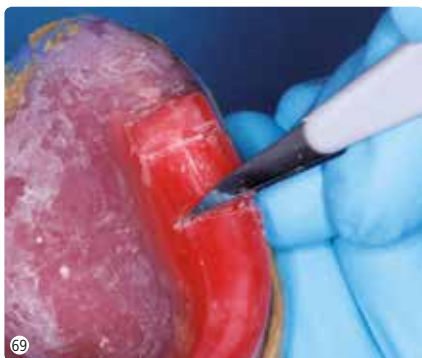
Next, carve cross-shaped tapered retentions (Fig. 69) into the wax rim and remove any interfering surplus impression material between the upper and lower tray. Now, secure both trays/ impressions in centric position by applying hard-setting addition silicone (e.g. Virtual CADbite) to the area of the retention boxes. Various techniques may be used to record the correct centric jaw position (e.g. deglutition bite-taking or hand-guided bite-taking) and are carried out in the habitual manner according to the operator's preferences. If necessary, hold the mandibular tray in position with your index finger and ask the patient to swallow, bring the maxilla forward and then close. This procedure is rehearsed a few times with the patient. Next, inject a hard-setting addition silicone into the retention boxes to carry out the bite registration (e.g. Virtual CADbite). Now, the patient is asked to swallow, bring the upper jaw forward and close, as rehearsed before (Figs 70 and 71).

Once the material is set, reseal and ensure the record is repeatable by checking a few times if the patient meets the hinge position without being guided. Furthermore, it should be possible to clearly align the two trays to each other outside of the oral cavity. After the records have been immobilized, the patient's midline and, if necessary, cuspid line and smile line may be marked on the records.

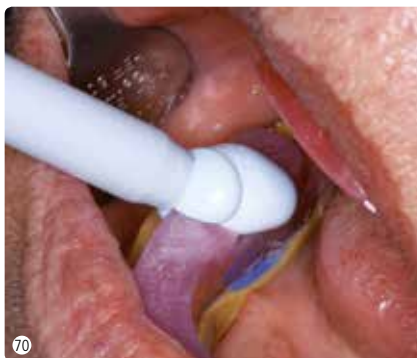A facebow transfer is advisable to adjust the Bonwill triangle to the individual requirements of the patient. This is achieved with the help of the maxillary record, similar to the procedure used in dentate patients.



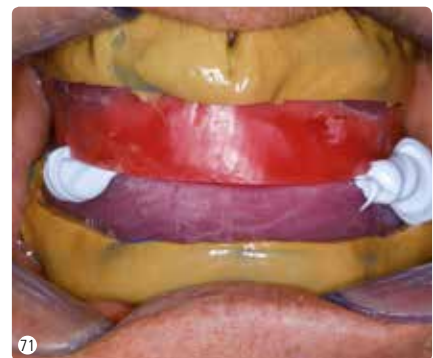68



69



70



71

## Tooth selection

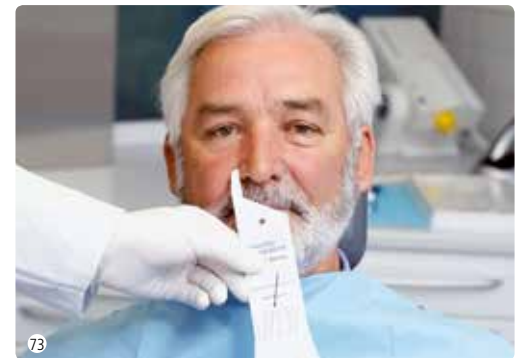In contrast to removable partial dentures in the partially dentate jaw, references to the original tooth size, shade and shape are usually not present in the edentulous jaw. Additionally, changes induced by tooth loss, residual ridge atrophy and atony of the muscles may impair the section of appropriate artificial teeth. The correct positioning of dentures in an "empty" oral cavity and consequently the re-establishment of speech, function and esthetics presents a challenge to the technician in particular.

As the articulated casts provide the only points of reference to the technician, it is essential for the clinician to pass on as much information as possible to the lab. Data regarding the midline, cuspid line, interalar width and smile line are particularly important. Ideally, the clinician, technician and patient select the tooth shade and shape together. Specific anatomic characteristics and individual patient requirements should be taken into account already at this stage.

Patients are encouraged to bring in any personal photographs clearly showing their natural teeth to select their new teeth. This information is an invaluable help in reconstructing the shape, size and position of the teeth. A correlation between the shape of the teeth and the head or body type have not been confirmed in studies.

Investigations by Gerber<sup>12</sup> and Lee<sup>13</sup> have shown that the anterior tooth width is easiest determined on the basis of the interalar width of the nose base. To determine the interalar width, use the FormSelector integrated into the Facial Meter (alameter) to measure the width of the nose base (Fig. 73). The meter does not display a metric value but instead directly suggests a "small", "medium" or "large" tooth set. Depending on the type of mould used (e.g. SR Phonares® II), the length, shape ("bold" or "soft") and age-related characteristics ("youthful", "universal", "mature") should be specified.

While soft and rounded moulds are generally perceived as feminine and bold angular moulds as masculine, clear evidence for typically female or typically male tooth shapes has not been substantiated by any study. Individual exceptions should be taken into account. Living tooth mould charts present an additional auxiliary for tooth selection. These lifelike tooth sets considerably facilitate patient-specific tooth selection (Fig. 74).

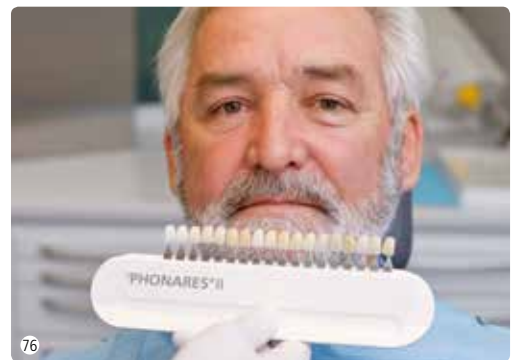

Age-related characteristics such as worn canines and incisal edges are created by grinding after the dentures have been completed.

The anterior tooth length is determined on the basis of the high smile line and the length of the lip. Generally, one to two millimetres of the teeth should be visible below the relaxed upper lip. Experience has shown that, in most cases, bisecting the intervestibular distance to establish the occlusal plane provides roughly the correct anterior tooth length (anterior tooth length in a normal bite: established occlusal plane plus 1 – 2 mm) so that only minor adjustments are required (deep bite / Class II: 3 – 4 mm; crossbite / Class III: 0 – 0.5 mm).<sup>11</sup>

The papillameter represents an additional measuring device to take measurements of the length of the patient's lip. The papillameter is placed on the patient's papilla incisiva and the length of the relaxed and smiling upper lip is determined. The technician can transfer the measured lengths by placing the papillameter on the papilla incisiva of the working model.

When selecting the tooth shade, the ideas of the dentists and patients often differ widely. Dentists feel that patients often request a tooth shade that is too light because they associate "bright white teeth" with healthy teeth. However, do not try to coax the patient to agree to the shade that you think is best; simply advise and guide them. In the worst case, the patient may perceive an otherwise impeccable denture as an unwanted foreign body because of the unwanted tooth shade and refuse to wear it (Figs 75 and 76).



# ■ Fourth appointment

The following aspects should be considered in the fabrication of complete dentures to attain an esthetic rehabilitation:

- 1. Correct position and design of the functional border, particularly in the upper anterior jaw**
- 2. Parallel position of the occlusal plane to Camper's plane**
- 3. Correct alignment of the vertical jaw relation**
- 4. A "positive" convex smile line**
- 5. Correct inclination of maxillary central incisors**
- 6. Correct positioning of canines**
- 7. Natural buccal corridor**
- 8. Natural-looking denture base**
- 9. Customized artificial gingiva or teeth (if desired)**

## Wax try-in

To verify:

- maxillomandibular relation,
- centric occlusion,
- (dynamic occlusion),
- esthetics (tooth shade, shape, setup),
- phonetics.

It is an advantage if the technician is present at the try-in of the waxed up dentures. In this way, possible modifications can be discussed there and then. The dentures are set up and completed according to BPS® criteria and handed over to the clinician in the articulator. The setup should satisfy the following criteria:

- The lower posterior teeth are set up statically correct at the centre of the alveolar ridge and do not extend beyond "Pound's line" on the lingual side. In some cases, this requires the upper posterior teeth to be positioned slightly away from the atrophied jaw in the molar region.
- In the anterior region, a vertical and horizontal overlap of 1 to 2 millimetres should be present in a normal bite (Class I) (deep bite/Class II: 3 – 4 mm; crossbite / Class III: 0 – 0.5 mm).<sup>11</sup>
- In static occlusion, the supporting cusp of each posterior tooth should show antagonist contact.
- A semi-balanced occlusion has proven capable of providing the necessary function. This means that the premolars (and possibly the canine) are engaged on the working side and the last molar on the balancing side. A completely balanced occlusion is also feasible. However, a completely balanced occlusion requires more time to setup and to adjust by grinding without offering a decisive advantage in stability. The dynamic occlusion can only be verified to a limited degree at the try-in in the patient's mouth. Evaluating the excursive movements is made difficult by the combined presence of wax and body temperature. Additionally, the denture base does in most cases not provide a sucking effect at this stage. The teeth may become loose or shift or the denture base made of self- or light-curing compound may rise from the tegument. It is therefore advisable to first evaluate the wax-up in the articulator and to assess the wax-up in the patient's mouth only upon completion of the evaluation in the articulator. Most cases will require only minor adjustments by grinding if the centric relation has been established accurately, high-quality tooth moulds used and the setup (template) performed correctly.



## Evaluation in the patient's mouth

If the maxillary denture does not provide a suction effect, it may be held in place with the help of a denture fixative. The mandibular denture should firmly rest on the residual ridge; you may additionally stabilize it with your thumb and index finger.

### 1. Checking the vertical dimension at rest and the occlusal height

Verify the vertical height at rest and at occlusion either by assessing the patient's phonetics or by measuring the freeway space (2–3 mm).

### 2. Evaluation of centric position

Ask the patient to lightly close on the back teeth while the lips are being retracted. Observe if the patient moves into the centric occlusal position or if the patient glides from a premature contact into maximum multipoint contact. To be able to see this, closely observe the initial contact between the dental arches. The dentures must not move or tilt. Instruct patients who tend to bite down in a protruding position to occlude down to one centimetre and then check under the chin if the jaw is in a relaxed, retral position capable of rotating

with the help of your index finger and thumb. After that, ask the patient to close again while watching if the patient glides into maximum intercuspitation at the initial contact (Fig. 77). Contacts during static occlusion can be visualized with articulating paper.<sup>8</sup>

### 3. Evaluation of stability

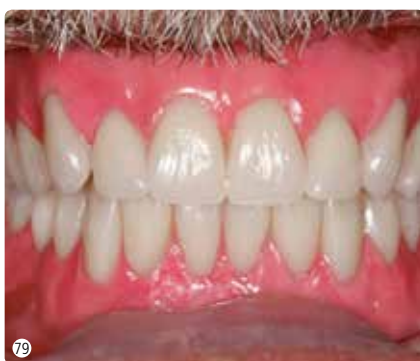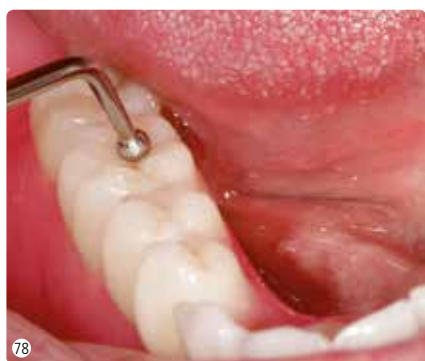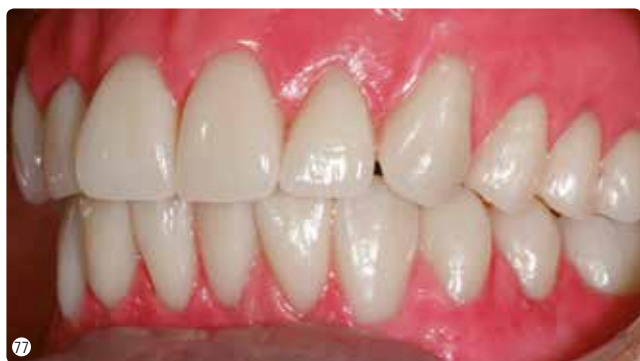Using a large round condenser, apply pressure on the central fossae of the first molars to confirm that the denture is steady and firm (Fig. 78).

### 4. Evaluation of esthetics

- Tooth shade, shape and position
- Midline
- Length of upper anterior teeth
- Correct lip support
- Positive smile line
- Position of occlusal plane
- Buccal corridor
- Correct alignment of the upper incisors in relation to the inter-pupillary line and facial arch (Figs 79 and 80)

### 5. Evaluation of phonetics

Chat with the patient to see if the lower and upper teeth touch ("clatter") during speech. Have patients count from 60 to 70 or count backwards while they are overpronouncing. When pronouncing an "S" sound (as in "Mississippi"), the lower jaw should be closest to the upper jaw but the tooth rows should not touch and no hissing should be audible. When pronouncing an "F" sound, the incisal edges of correctly set up upper anterior teeth should rest on the transition between the moistened and dry part of the vermillion border.



## **Shortcomings in the wax setup and correction of shortcomings**

If the guidelines for tooth setup and the systematic clinical procedure of the BPS concept have been observed, most cases will usually require only minor esthetic adjustments. Some of these changes can be performed directly at the chairside. Major changes should be delegated to the laboratory.

If the wax setup shows major shortcomings, provide the technician with sufficient information about the required changes. Ideally, the technician should attend the wax try-in appointment to discuss any necessary changes with the patient and dentist. If the dentist or patient have reservations about the esthetic appearance of the dentures, a current picture of the patient may provide helpful information to the technician.

Shortcomings in the stability of the denture (examination with round condenser) require the teeth to be set up again in the correct position at the centre of the mandibular alveolar ridge.

If the vertical height is too low, a vertical adjustment of the occlusion is required. To increase the vertical dimension, apply aluminium wax onto the posterior region of the mandible until the correct vertical occlusion is reached. Next, make a hand-guided impression in the customary manner.

If the vertical height is too high and requires to be decreased, small adjustments (1 to 2 mm) can be made in wax in the articulator. Once the changes are made, check the result again on the patient.

Faulty centric jaw relations rarely occur if the needle point tracing has been done correctly. If discrepancies are nonetheless discovered at the try-in, a new record must be taken.



## ■ Fifth appointment

### **Final evaluation** (Figs 81–87)

Inspect the completed dentures before inserting them into the patient's mouth. Inspect the denture bases – they should be smooth and free of any spicules or sharp areas; the denture borders should be round and must not end in a sharp ledge.

The intraoral evaluation of the completed dentures follows a similar procedure as the evaluation of the wax-up. In addition, examine the stability of the dentures under loading in the posterior, anterior and canine region (e.g. by exerting pressure on these regions with a finger or round condenser).

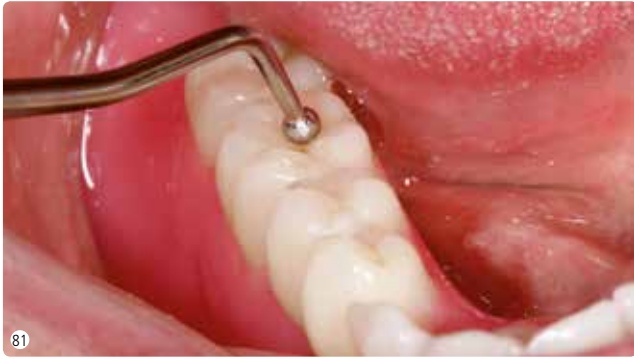Check the labial and buccal frenum notches.

In static occlusion, the premolars and first molars should be in firm contact; in other words, a thin piece of articulating film should be held by all teeth.<sup>8</sup>

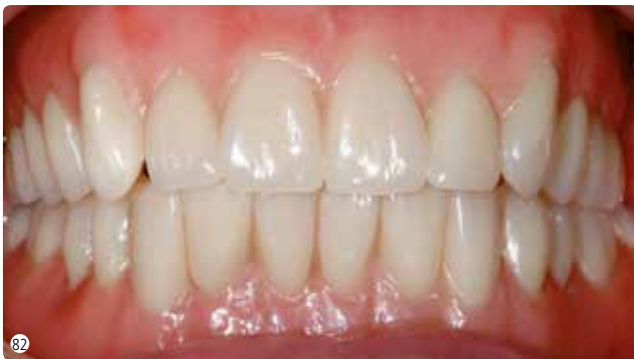During laterotrusion of the mandible, at least the premolars should be in contact on the working side and the last molars on the balancing side. Again use articulating film to check this.

During protrusion, the dentures are stabilized by the contact of the premolars and anteriors.

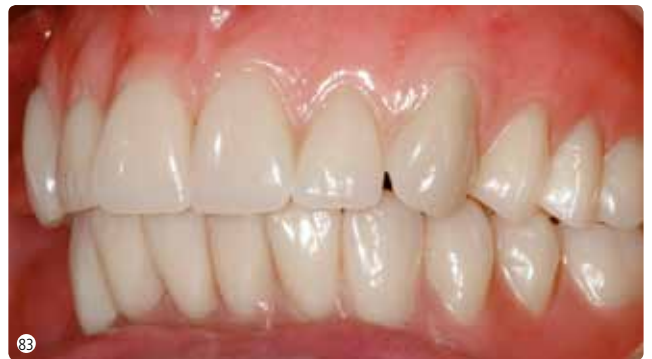Finally, check the esthetic appearance and the patient's phonetics.



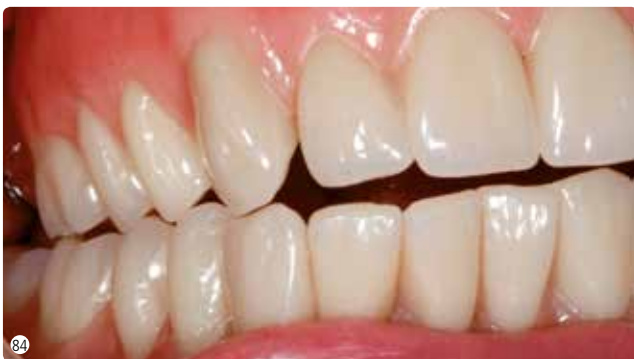81  
Stability



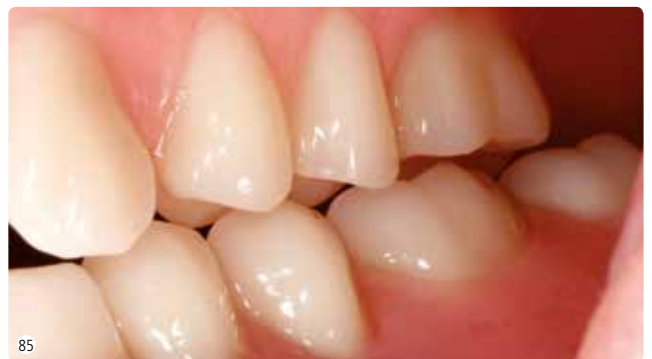82  
Centric



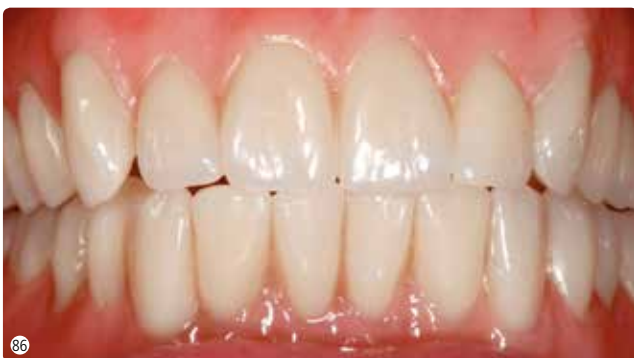83  
Centric



84  
Working side



85  
Balancing side



86  
Protrusion



87  
Esthetics and phonetics

## ■ Continuing care and maintenance

### Wearing dentures at night

The question of whether or not to wear dentures at night frequently arises. There are arguments in favour and against it so that ultimately the decision lies with the patient. If the dentures are not worn at night, the mucous membrane can relax and recuperate from the pressure exerted by the dentures. Additionally, blood supply improves while the dentures are out of the mouth and the saliva has a chance to moisten the mucous membrane. Parafunctions are not possible in the absence of a bite.

On the other hand, patients may not want to remove the dentures at night for psychological reasons. For instance, they may not want to be seen without teeth by their partner. The lack of support when swallowing without dentures may be another argument in favour of wearing the dentures at night.

### Cleaning

Make sure that patients are aware of the importance of regular mechanical denture cleaning. Immersing the dentures in cleaning solution does not substitute for mechanical cleaning. Special denture brushes or tooth brushes and abrasive-free denture cleaning pastes, gels or foams are best suited for denture cleaning. Once a week the dentures should be soaked in a denture cleaning solution according to the manufacturer's instructions. Gentle and effective care can be ensured by cleaning the dentures in an ultrasound cleaning device. This method effectively and gently removes soft deposits, tartar and tea/nicotine build-ups. Additionally, the mucous membrane should also be cleaned with a toothbrush every day.

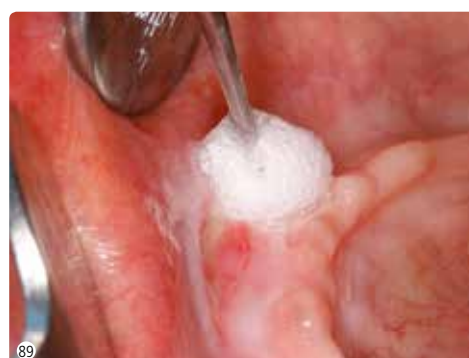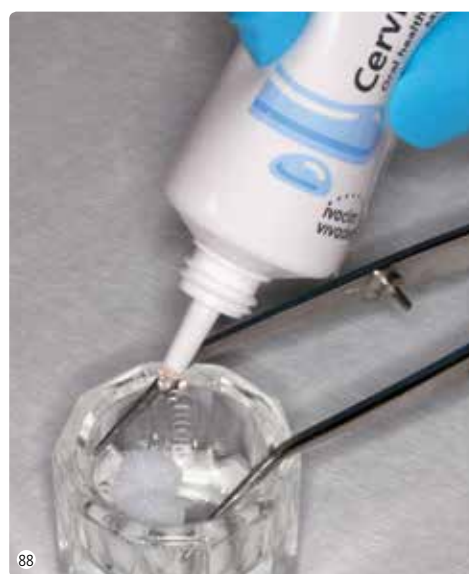### Post-insertion care

Since the complex movement patterns of the oral muscles can never be completely recorded in a functional impression, even if the greatest of care is taken, it may never be ruled out that the patient may not suffer from pressure ulcers when wearing new dentures. Patients should be told that "pressure spots" may occur but do not present a problem and can be alleviated with appropriate measures.

It is advisable to arrange for a follow-up appointment three days after the insertion. At the follow-up, the overall well-being and the specific oral condition of the patient are assessed.

Regular denture recall appointments should be scheduled on a yearly, or better still, half yearly basis. Patients tend to forget that even "artificial teeth" need to be checked on a regular basis. Regular check-ups are essential to discover changes in the stomatognathic system in good time and take appropriate measures as necessary.

With early recognition, possible pressure spots or denture stomatitis can be treated effectively and promptly by applying chlorhexidine-containing mouth gels, varnishes and rinses (Figs 88 and 89).<sup>14</sup> At the same time, the dentures can be cleaned professionally in the dental practice at the check-up.



# Literature references

- <sup>1</sup> Micheelis W, Schiffner U: Vierte Deutsche Mundgesundheitsstudie (DMS IV), Institut der Deutschen Zahnärzte (IDZ Materialreihe Band 31), Deutscher Arzt-Verlag, Köln (2006)
- <sup>2</sup> Kerschbaum Th: Zur Überlebensrate von Totalprothesen. Dtsch. Zahnärztl. Z. 62, 458-464 (2007)
- <sup>3</sup> Rarisch B: Ergebnisse und klin. Konsequenzen einer siebenjährigen Longitudinalstudie zur Abrasion von Kunststoffzähnen bei Totalprothesen. Dtsch. Zahnärztl. Z. 37, 776-777 (1982)
- <sup>4</sup> Statistisches Bundesamt Gruppe VIA, „Demografische Modellrechnungen“: Bevölkerung Deutschlands bis 2060, 12. Bevölkerungsvorausberechnung, Wiesbaden (November 2009)
- <sup>5</sup> Doblhammer, G, Muth E, Kruse A: Abschlussbericht Lebenserwartung in Deutschland: Trends, Prognose, Risikofaktoren und der Einfluss ausgewählter Medizininnovationen, Rostocker Zentrum zur Erforschung des Demografischen Wandels, Rostock (2008)
- <sup>6</sup> Vincent G C, Velkhoff V A: The next four decades – The older population in the United States: 2010 to 2050, Population Estimates and Projections. U.S. Department of commerce Economics and Statistics Administration U.S. Census Bureau (2010)
- <sup>7</sup> Tuljapurkar S, Li N, Boe C: A universal pattern of mortality decline in the G7 countries. Nature 405, 789-792 (2000)
- <sup>8</sup> Setz J, Engel E: Die Totalprothese (Klinischer Leitfaden), Ivoclar Vivadent, Schaan, 2007
- <sup>9</sup> Maaz A: Depressive Syndrome im Alter: Eine Sekundäranalyse der gesundheitlichen Versorgung auf der Basis von Krankenkassen-routinedaten, Med. diss. Berlin (2010)
- <sup>10</sup> Tallgren A, The continuing reduction of the residual alveolar ridges in complete denture wearers: A mixed-longitudinal study covering 25 years, THE JOURNAL OF PROSTHETIC DENTISTRY, 2003; 5:427-435
- <sup>11</sup> Goerge S, Tomkins N: Tief- und Kreuzbiss (Klasse II und Klasse III) Special Edition. Ivoclar Vivadent, Schaan
- <sup>12</sup> Gerber, A.: Proportionen und Stellung der Frontzähne im natürlichen und künstlichen Zahnbogen. Quintessenz/Heft 1, 1965
- <sup>13</sup> Lee, J: Dental Aesthetics. John Wright & Sons Ltd, Bristol (1962)
- <sup>14</sup> Watzke R, Peschke A, Blankenstein F, Huwig A: Durch Anwendung eines Chlorhexidinpräparats unterstützte konventionelle Therapie einer Prothesenstomatitis. Quintessenz 2009; 60(4); 425–435

## Additional references:

Fiedler K: BPS-Totalprothetik (mit System zum Ziel), Neuer Merkur Verlag, 2003

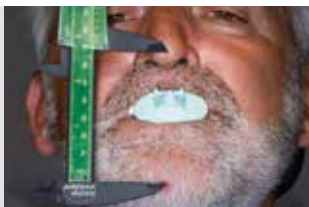




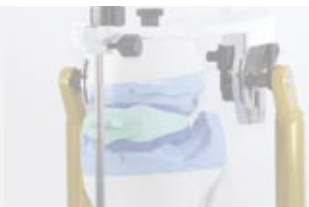


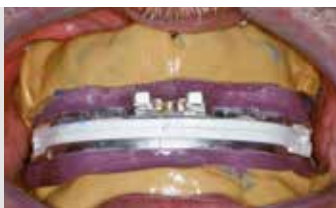**Clinical history**  
**Preliminary impressions**  
**Provisional maxillomandibular records**



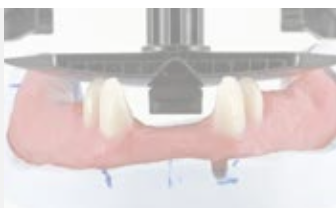**Model fabrication**  
**Short model analysis**  
**Customized trays**  
**Intraoral registration**



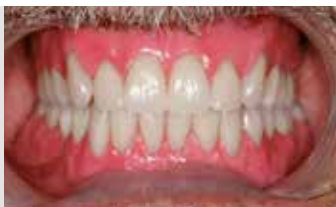**Final impressions**  
**Final maxillomandibular records**  
**Tooth selection**



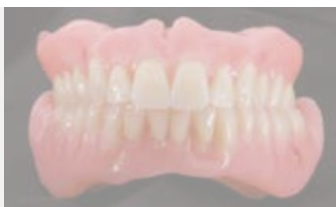**Comprehensive model analysis**  
**Model orientation**  
**Tooth setup**  
**Gingiva design**



**Try-in**



**Completion**



**Insertion**  
**Continuing care**



**Ivoclar Vivadent AG**  
Bendererstrasse 2  
9494 Schaan  
Liechtenstein  
Tel. +423 235 35 35  
Fax +423 235 33 60  
www.ivoclarvivadent.com

**Ivoclar Vivadent Pty. Ltd.**  
1 – 5 Overseas Drive  
P.O. Box 367  
Noble Park, Vic. 3174  
Australia  
Tel. +61 3 9795 9599  
Fax +61 3 9795 9645  
www.ivoclarvivadent.com.au

**Ivoclar Vivadent GmbH**  
Tech Gate Vienna  
Donau-City-Strasse 1  
1220 Wien  
Austria  
Tel. +43 1 263 191 10  
Fax: +43 1 263 191 111  
www.ivoclarvivadent.at

**Ivoclar Vivadent Ltda.**  
Alameda Caiapós, 723  
Centro Empresarial Tamboré  
CEP 06460-110 Barueri – SP  
Brazil  
Tel. +55 11 2424 7400  
Fax +55 11 3466 0840  
www.ivoclarvivadent.com.br

**Ivoclar Vivadent Inc.**  
1-6600 Dixie Road  
Mississauga, Ontario  
L5T 2Y2  
Canada  
Tel. +1 905 670 8499  
Fax +1 905 670 3102  
www.ivoclarvivadent.ca

**Ivoclar Vivadent Shanghai Trading Co., Ltd.**  
2/F Building 1, 881 Wuding Road,  
Jing An District  
200040 Shanghai  
China  
Tel. +86 21 6032 1657  
Fax +86 21 6176 0968  
www.ivoclarvivadent.com

**Ivoclar Vivadent Marketing Ltd.**  
Calle 134 No. 7-B-83, Of. 520  
Bogotá  
Colombia  
Tel. +57 1 627 3399  
Fax +57 1 633 1663  
www.ivoclarvivadent.co

**Ivoclar Vivadent SAS**  
B.P. 118  
F-74410 Saint-Jorioz  
France  
Tel. +33 4 50 88 64 00  
Fax +33 4 50 68 91 52  
www.ivoclarvivadent.fr

**Ivoclar Vivadent GmbH**  
Dr. Adolf-Schneider-Str. 2  
D-73479 Ellwangen, Jagst  
Germany  
Tel. +49 7961 889 0  
Fax +49 7961 6326  
www.ivoclarvivadent.de

**Wieland Dental + Technik GmbH & Co. KG**  
Schwenninger Strasse 13  
D-75179 Pforzheim  
Germany  
Tel. +49 7231 3705 0  
Fax +49 7231 3579 59  
www.wieland-dental.com

**Ivoclar Vivadent Marketing (India) Pvt. Ltd.**  
503/504 Raheja Plaza  
15 B Shah Industrial Estate  
Veera Desai Road, Andheri (West)  
Mumbai, 400 053  
India  
Tel. +91 22 2673 0302  
Fax +91 22 2673 0301  
www.ivoclarvivadent.in

**Ivoclar Vivadent s.r.l.**  
Via Isonzo 67/69  
40033 Casalecchio di Reno (BO)  
Italy  
Tel. +39 051 6113555  
Fax +39 051 6113565  
www.ivoclarvivadent.it

**Ivoclar Vivadent K.K.**  
1-28-24-4F Hongo  
Bunkyo-ku  
Tokyo 113-0033  
Japan  
Tel. +81 3 6903 3535  
Fax +81 3 5844 3657  
www.ivoclarvivadent.jp

**Ivoclar Vivadent Ltd.**  
12F W-Tower, 1303-37  
Seocho-dong, Seocho-gu,  
Seoul 137-855  
Republic of Korea  
Tel. +82 2 536 0714  
Fax +82 2 596 0155  
www.ivoclarvivadent.co.kr

**Ivoclar Vivadent S.A. de C.V.**  
Av. Insurgentes Sur No. 863,  
Piso 14, Col. Napoles  
03810 México, D.F.  
México  
Tel. +52 55 5062 1000  
Fax +52 55 5062 1029  
www.ivoclarvivadent.com.mx

**Ivoclar Vivadent BV**  
De Fruittuinen 32  
2132 NZ Hoofddorp  
Netherlands  
Tel. +31 23 529 3791  
Fax +31 23 555 4504  
www.ivoclarvivadent.com

**Ivoclar Vivadent Ltd.**  
12 Omega St, Rosedale  
PO Box 303011 North Harbour  
Auckland 0751  
New Zealand  
Tel. +64 9 914 9999  
Fax +64 9 914 9990  
www.ivoclarvivadent.co.nz

**Ivoclar Vivadent Polska Sp. z o.o.**  
Al. Jana Pawla II 78  
00-175 Warszawa  
Poland  
Tel. +48 22 635 5496  
Fax +48 22 635 5469  
www.ivoclarvivadent.pl

**Ivoclar Vivadent Marketing Ltd.**  
Prospekt Andropova 18 korp. 6/  
office 10-06  
115432 Moscow  
Russia  
Tel. +7 499 418 0300  
Fax +7 499 418 0310  
www.ivoclarvivadent.ru

**Ivoclar Vivadent Marketing Ltd.**  
Qlaya Main St.  
Siricon Building No.14, 2<sup>nd</sup> Floor  
Office No. 204  
P.O. Box 300146  
Riyadh 11372  
Saudi Arabia  
Tel. +966 11 293 8345  
Fax +966 11 293 8344  
www.ivoclarvivadent.com

**Ivoclar Vivadent S.L.U.**  
Carretera de Fuencarral n°24  
Portal 1 – Planta Baja  
28108-Alcobendas (Madrid)  
Spain  
Telf. +34 91 375 78 20  
Fax: +34 91 375 78 38  
www.ivoclarvivadent.es

**Ivoclar Vivadent AB**  
Dalvägen 14  
S-169 56 Solna  
Sweden  
Tel. +46 8 514 939 30  
Fax +46 8 514 939 40  
www.ivoclarvivadent.se

**Ivoclar Vivadent Liaison Office**  
: Tesvikiye Mahallesi  
Sakayik Sokak  
Nisantas' Plaza No:38/2  
Kat:5 Daire:24  
34021 Sisli – Istanbul  
Turkey  
Tel. +90 212 343 0802  
Fax +90 212 343 0842  
www.ivoclarvivadent.com

**Ivoclar Vivadent Limited**  
Ground Floor Compass Building  
Feldspar Close  
Warrens Business Park  
Enderby  
Leicester LE19 4SE  
United Kingdom  
Tel. +44 116 284 7880  
Fax +44 116 284 7881  
www.ivoclarvivadent.co.uk

**Ivoclar Vivadent, Inc.**  
175 Pineview Drive  
Amherst, N.Y. 14228  
USA  
Tel. +1 800 533 6825  
Fax +1 716 691 2285  
www.ivoclarvivadent.us